Die Schilddrüse und ihre Nachbarn

Dr. Matthias Lang

Interdisziplinäres Ultraschallzentrum

Chirurgische Universitätsklinik Heidelberg

Was gibt’s zu sehen?

- Schilddrüse
- (Nebenschilddrüse)
- Lymphknoten
- Ösophagus
- Gefäße
- Thymus
- Speicheldrüsen

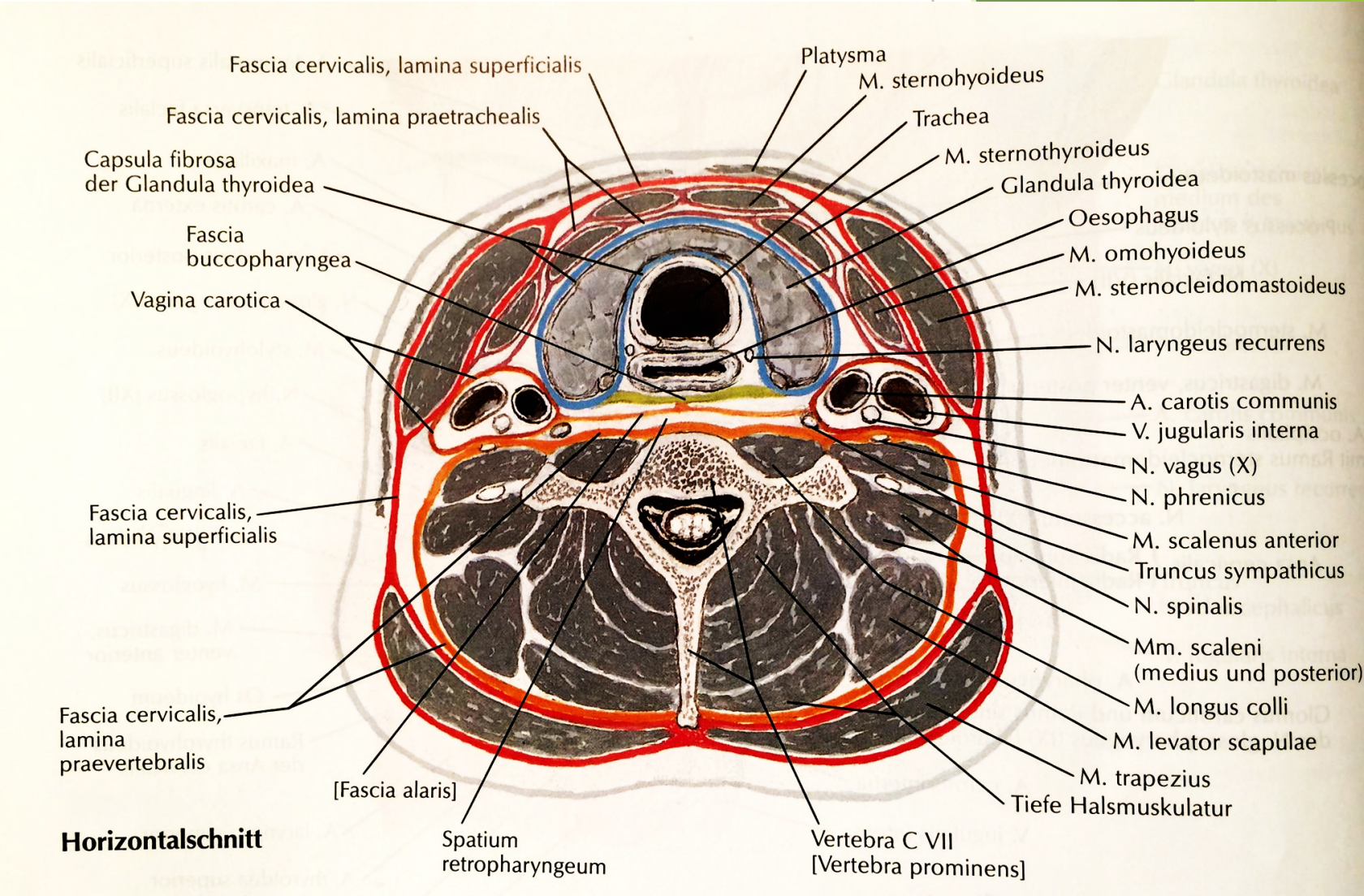

Was gibt’s zu sehen?

- Schilddrüse
- (Nebenschilddrüse)
- Lymphknoten
- Ösophagus
- Gefäße
- Thymus
- Speicheldrüsen

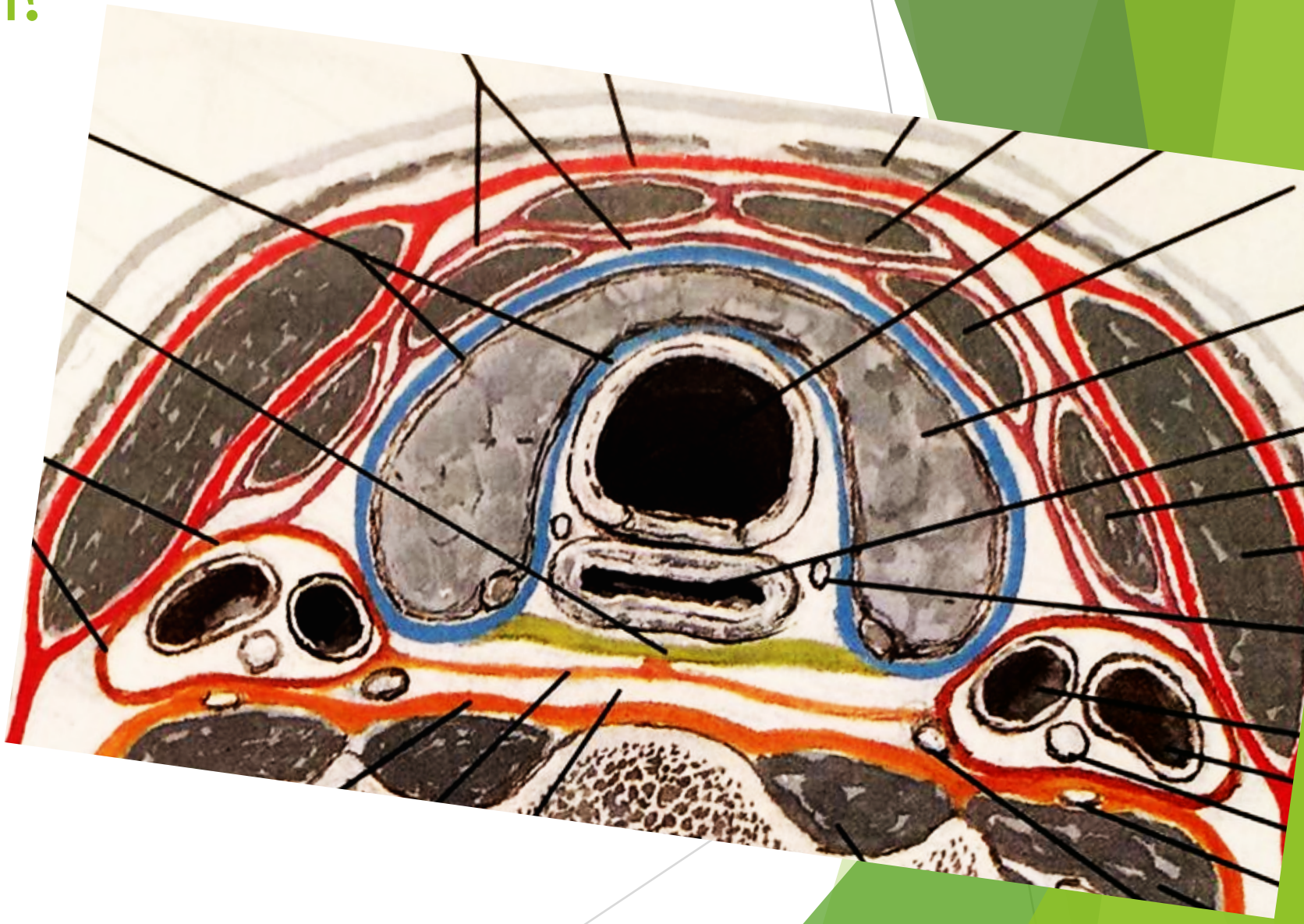

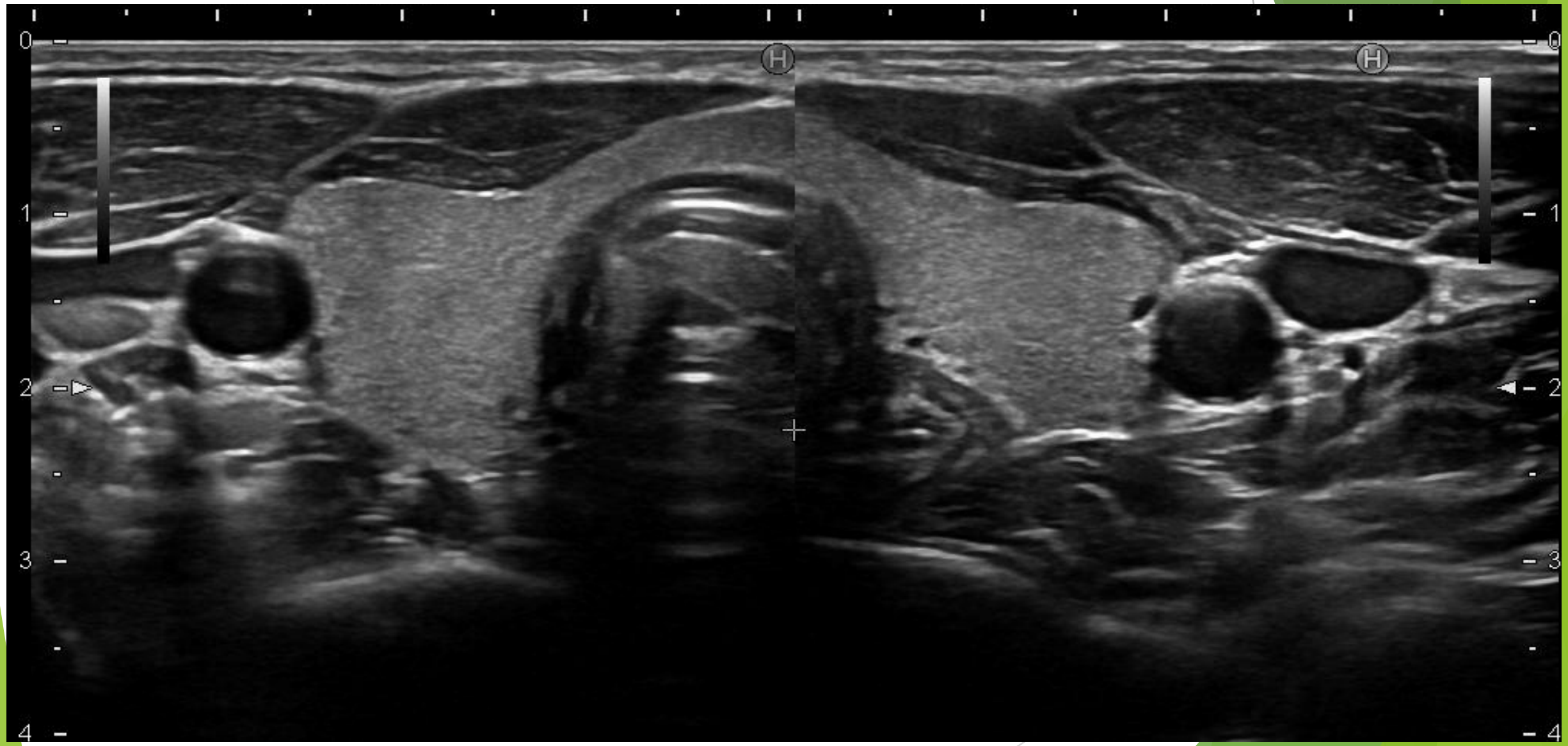
0
1
2
3
4
H
H
0
1
2
3
4

Messung

½ Länge x Breite x Tiefe
Norm: < 18 – 25 ml

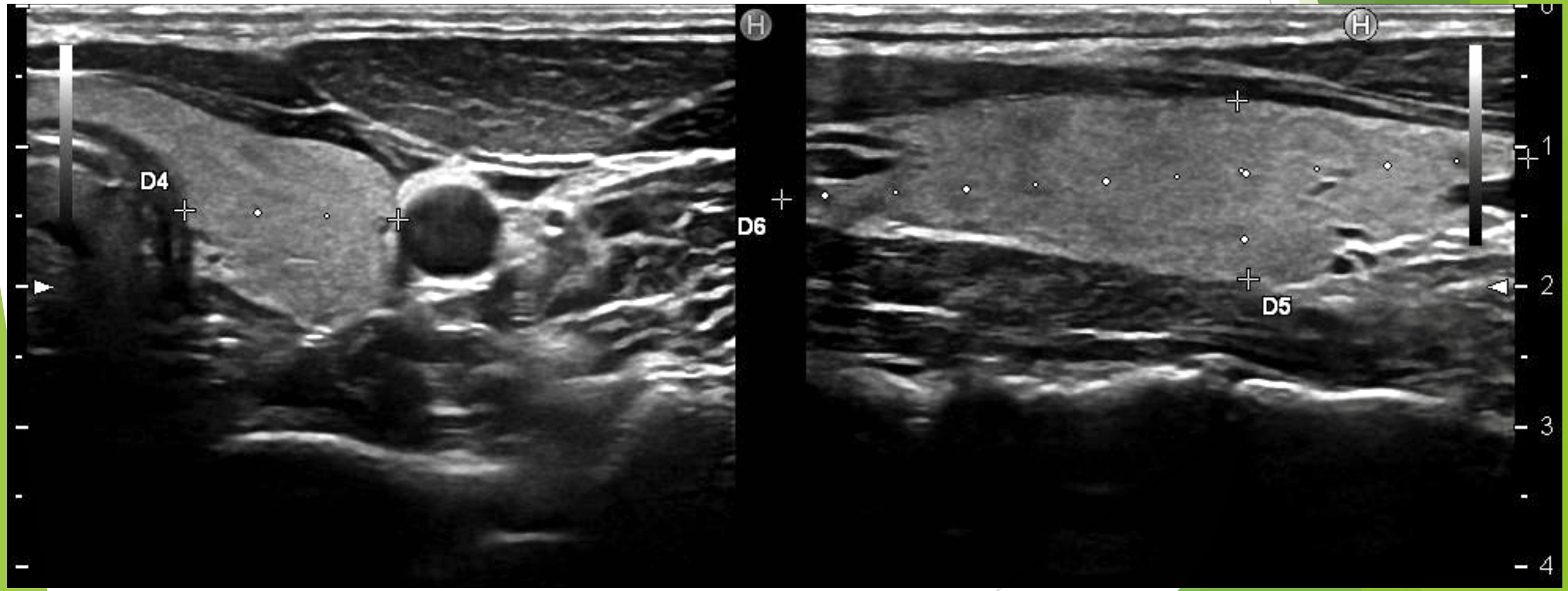

Messung

- <18-25 ml, Riesenstruma mit Konvexsonde messen
- Echoreicher als Muskel
- Perfusion abschätzen (Fluß A.thyroidea <40 cm/s)

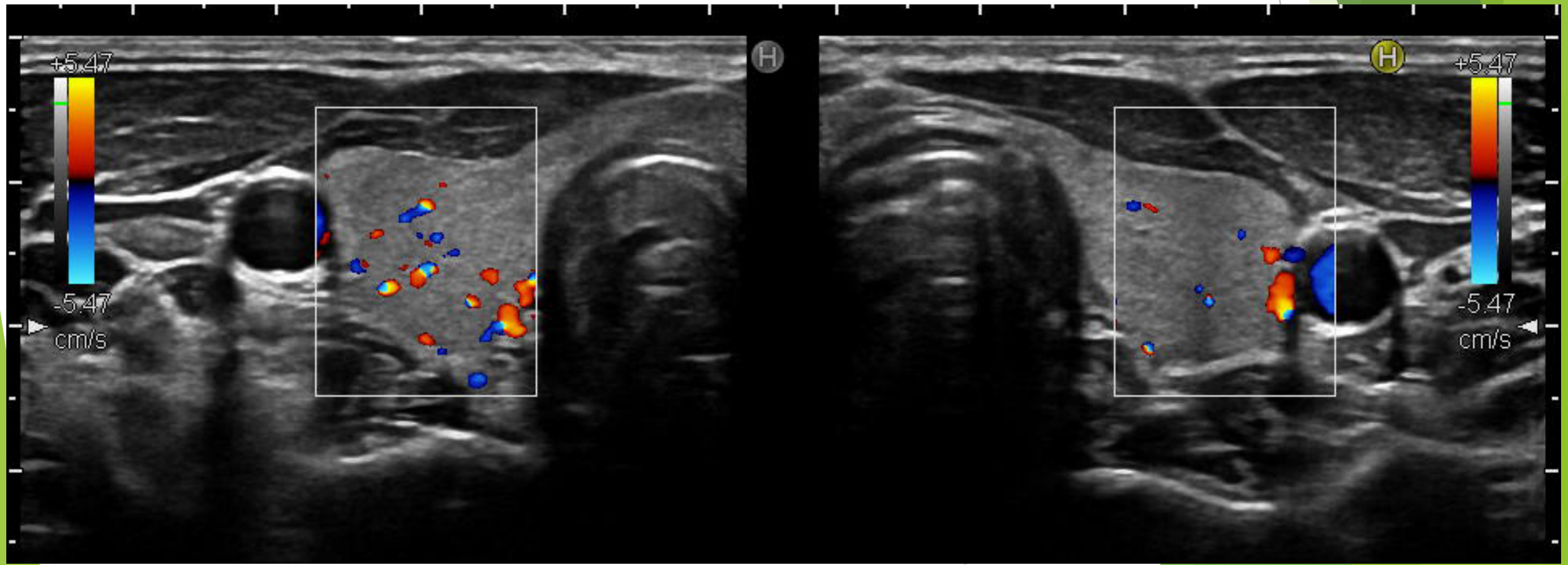

Was gibt's zu sehen?

- **Struma** Vergrößerung, Knoten, Zyste
- **Tumore** papillär, follikulär, medullär, anaplastisch
- **Metastasen** Niere, Brust, Bronchien, Melanom
- **Entzündung** Hashimoto, Basedow, De Quervain
- **Nix** Schilddrüsenaplasie, Thyroidektomie

Knoten benigne?

- Echoreich oder echofrei
- Weich (Elastografie)
- Grobe Verkalkungen
- Zysten schwammartig
- kompletter Gefäßsaum
- Länglich- oval
- Multiple Knoten
- Szintigr. warm/heiß

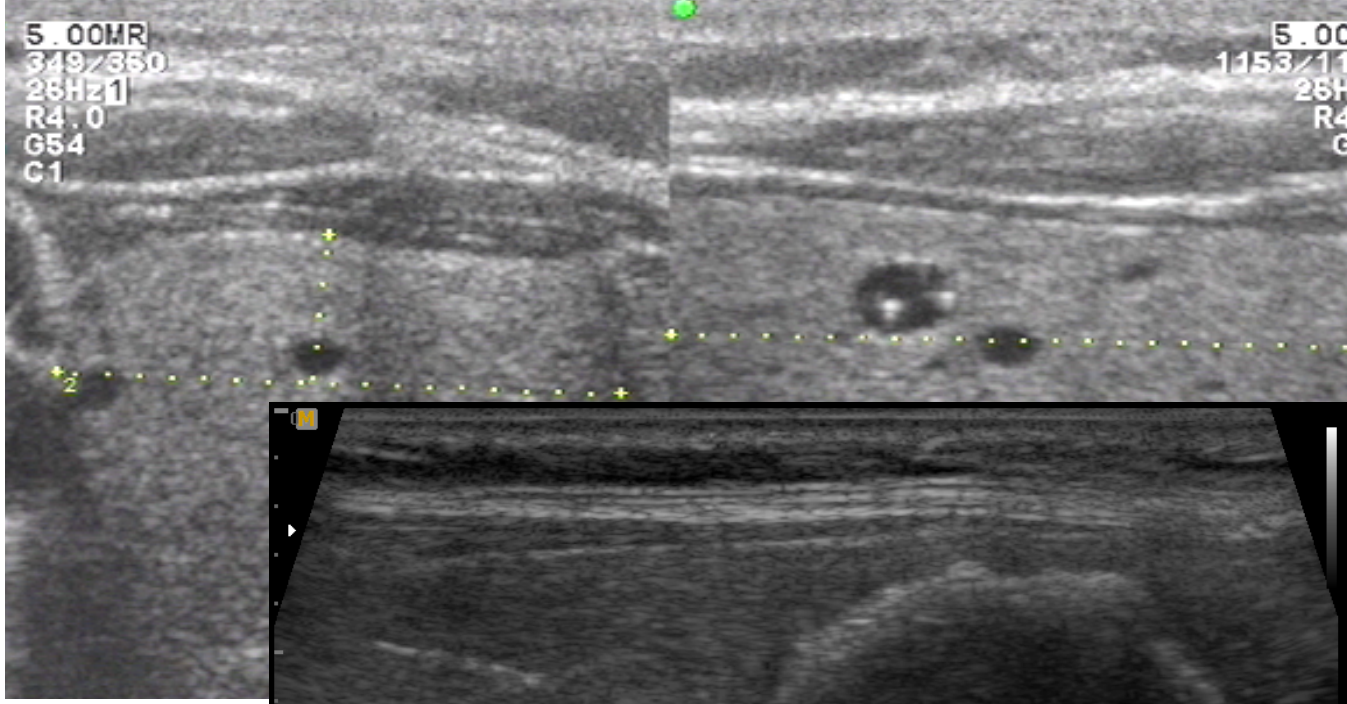

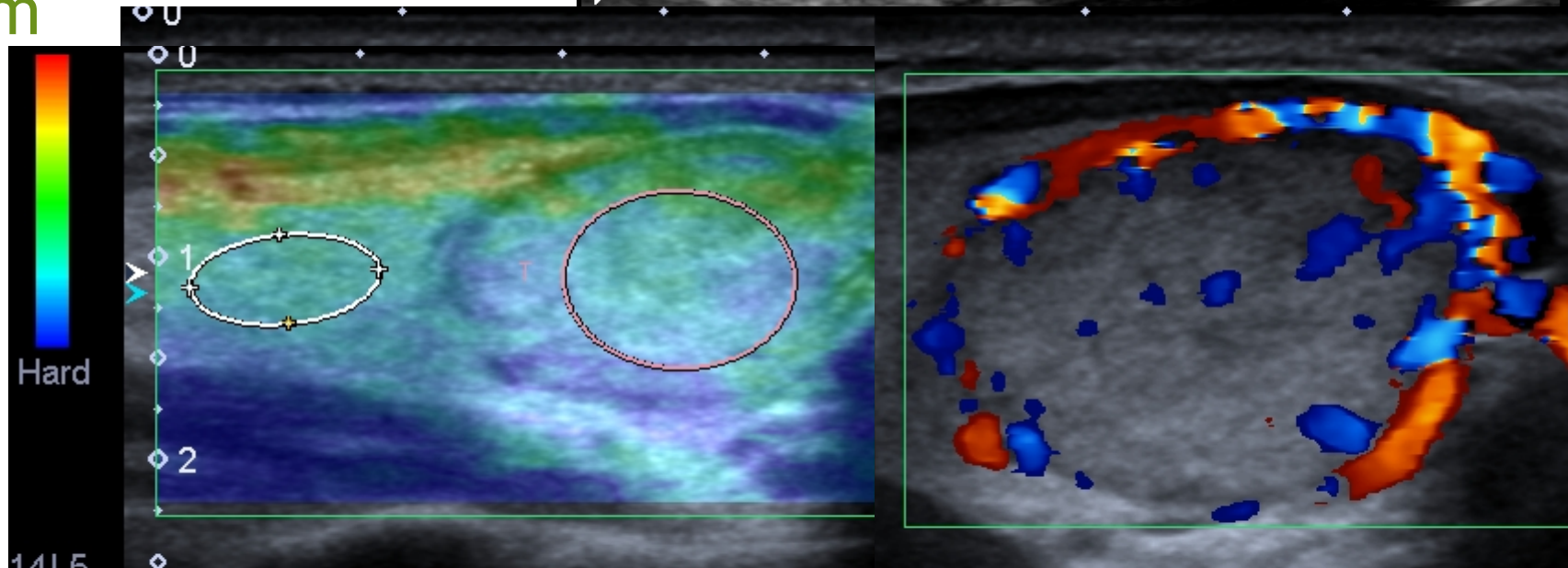

Knoten maligne?

- Echoarm und inhomogen
- Mikroverkalkungen
- Unscharf begrenzt
- Hart in der Elastografie
- Tiefer als lang
- Binnenperfusion
- Solitär
- Suspekte Lymphknoten

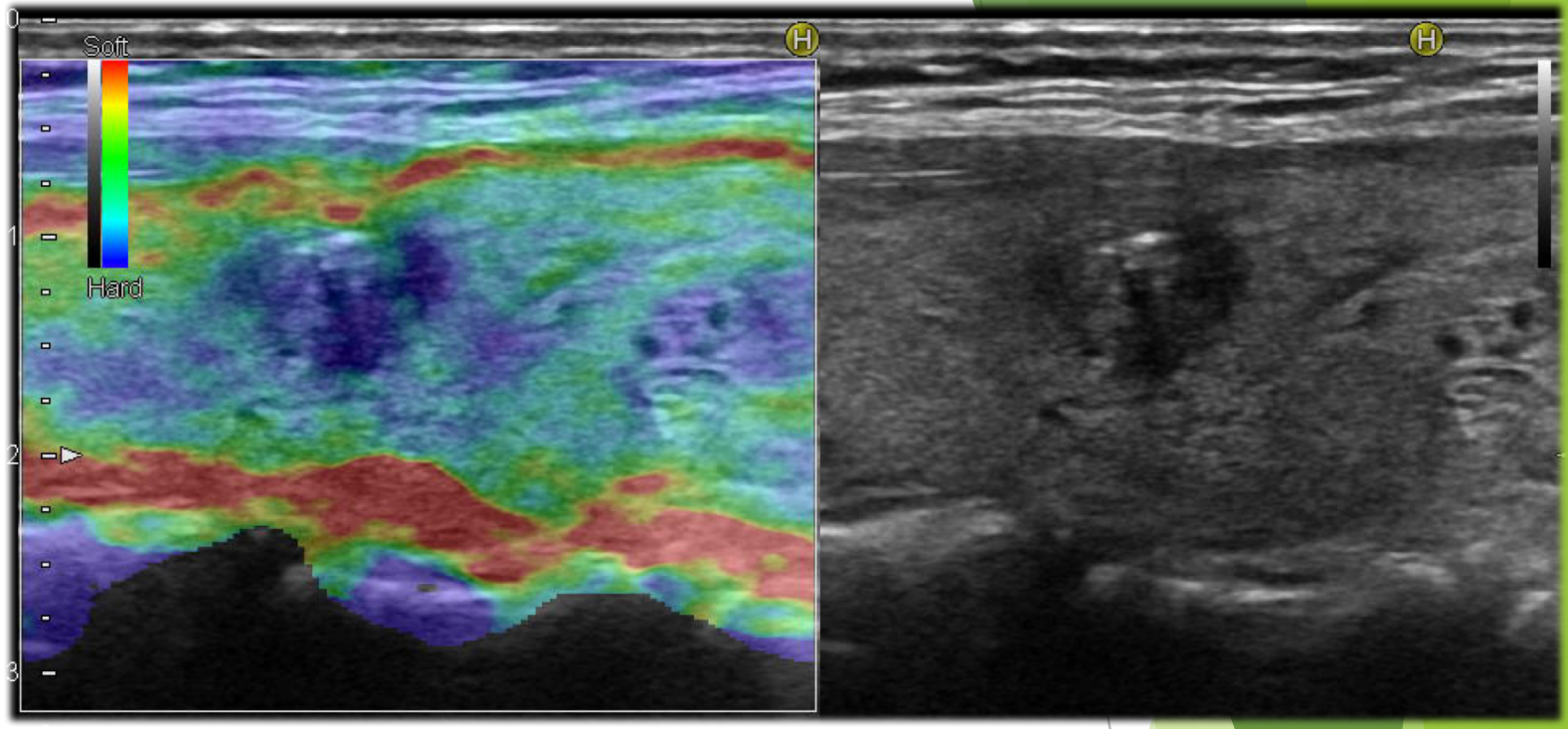

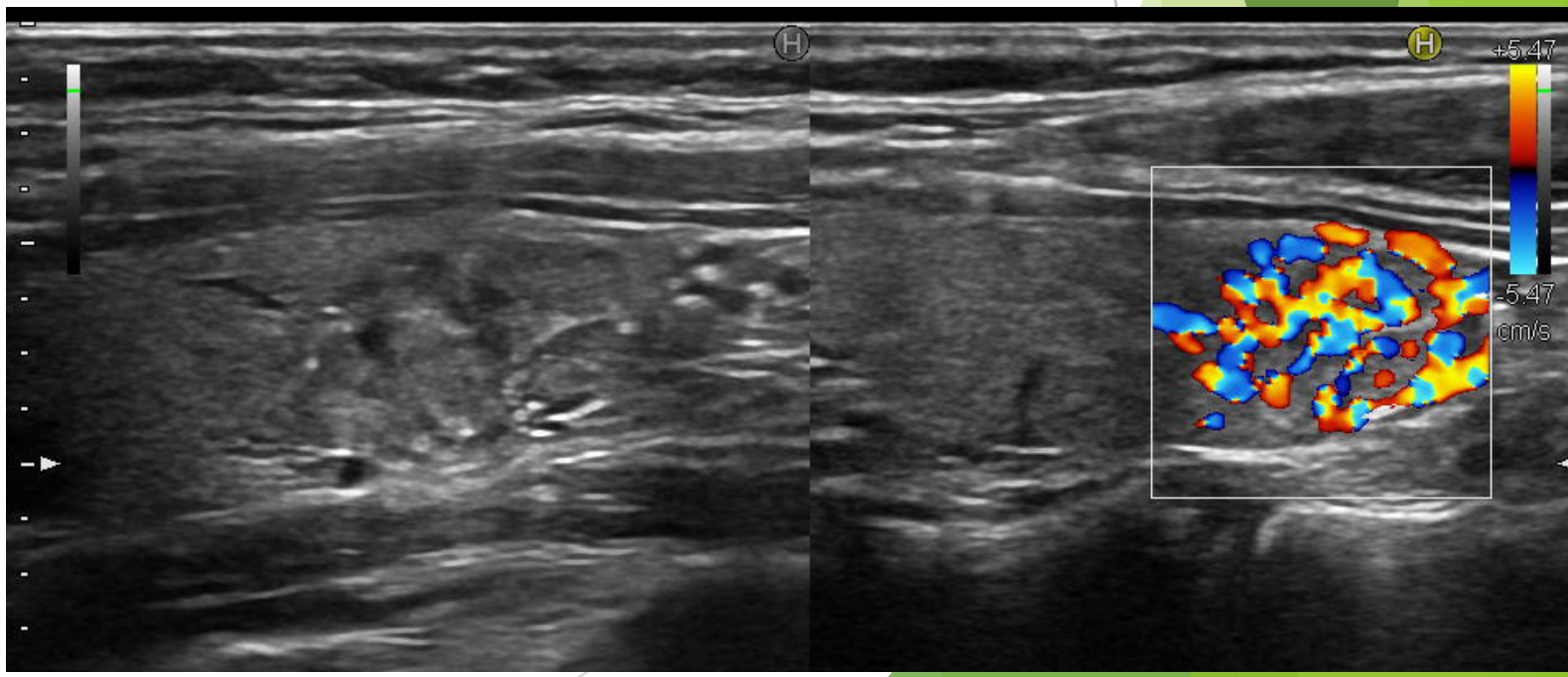

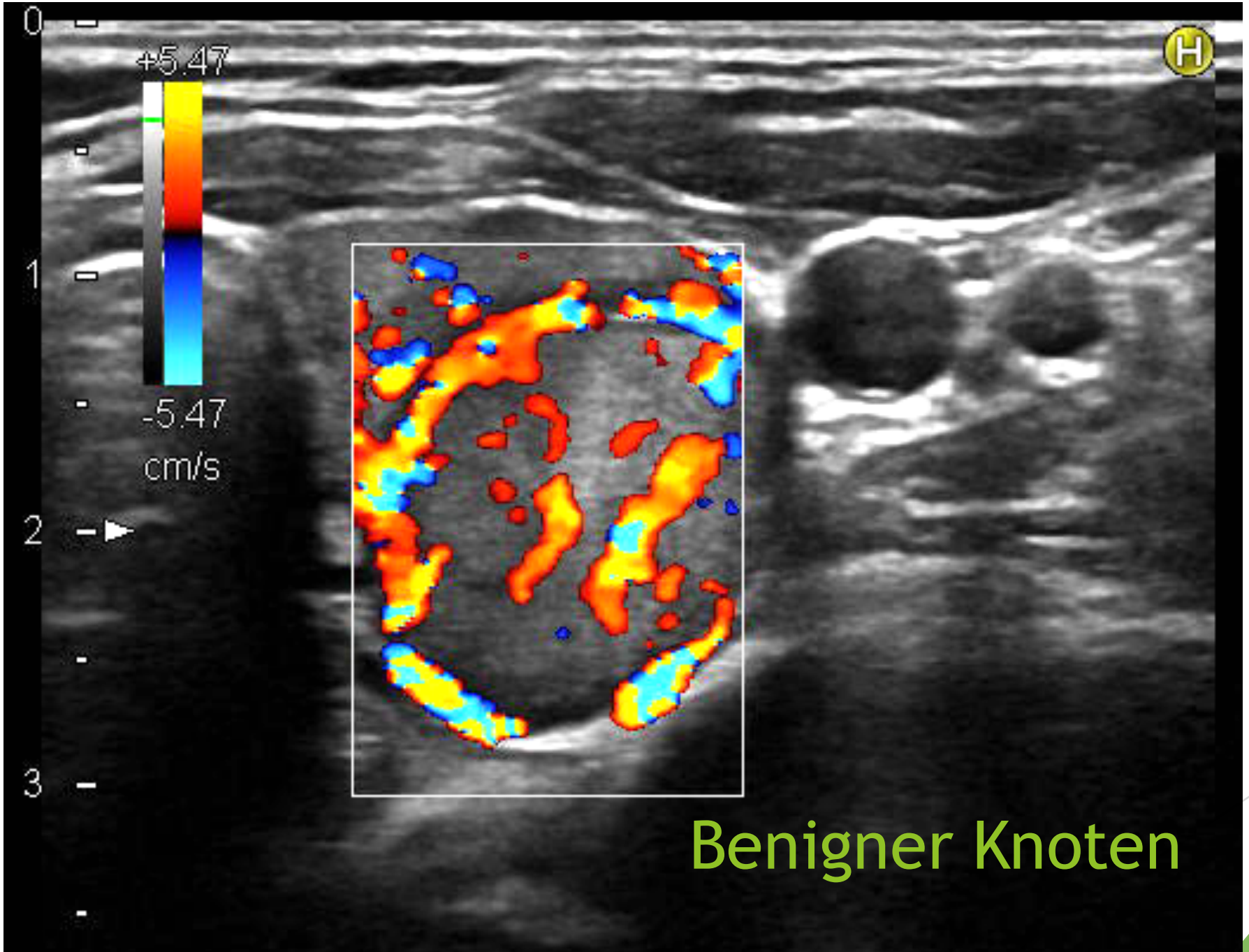

Benigner Knoten

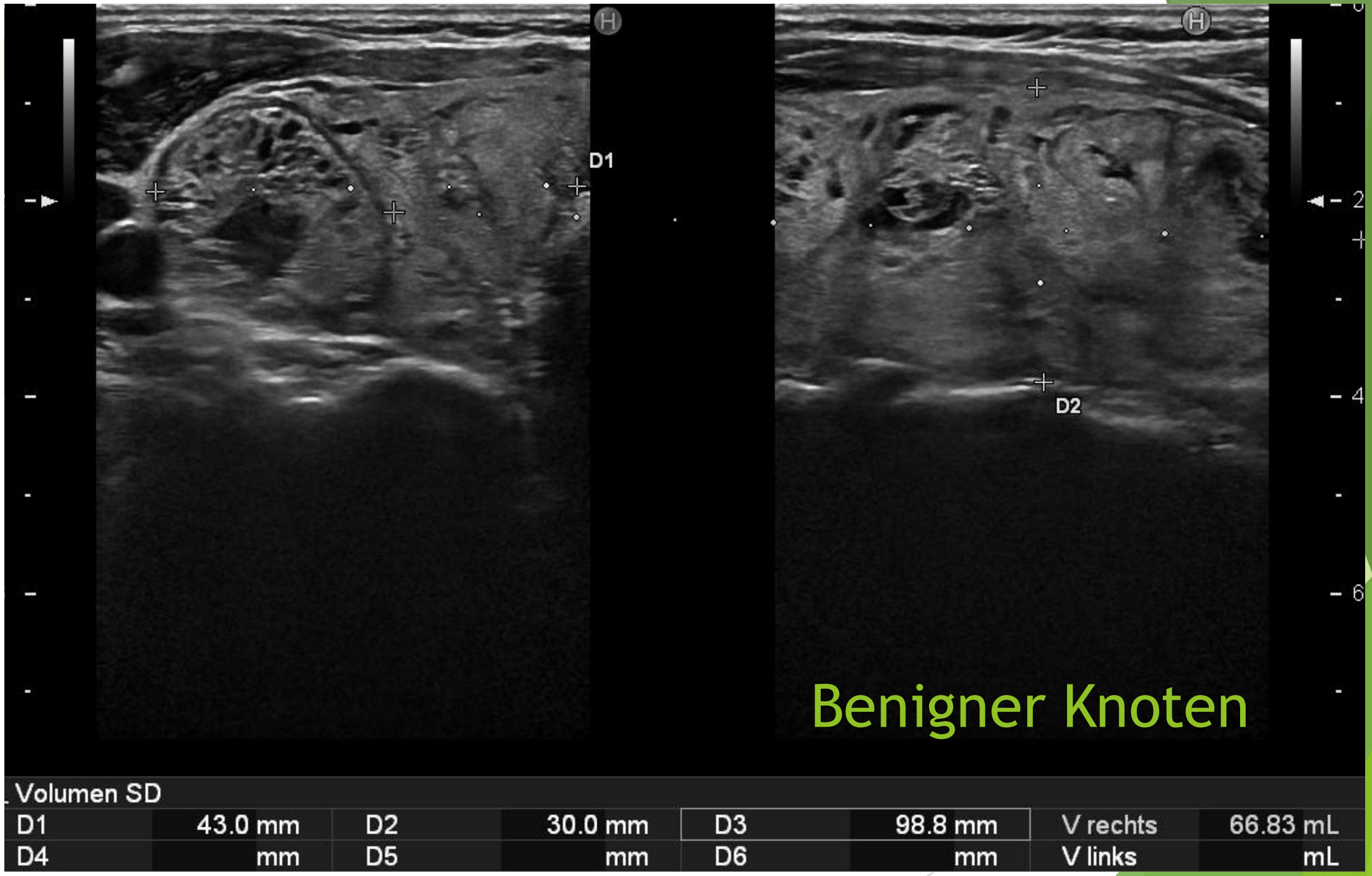

Benigner Knoten

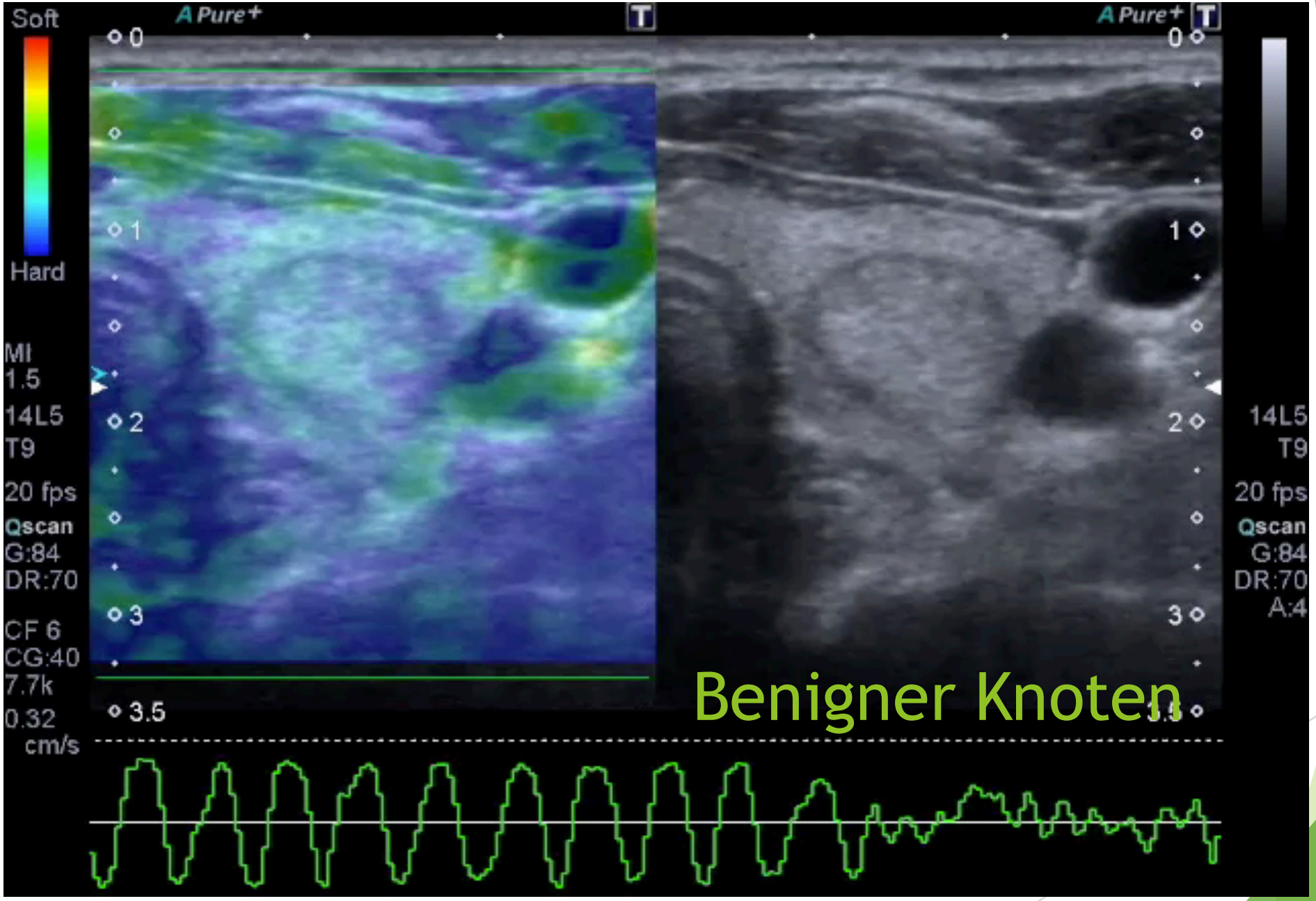

Benigner Knoten

Zystischer Knoten

Sonografisch suspekt, histologisch benigne

Suspekt weil:

-Mikroverkalkung
-Überschreitet Kapsel
-Solitärknoten bei jungem Mann

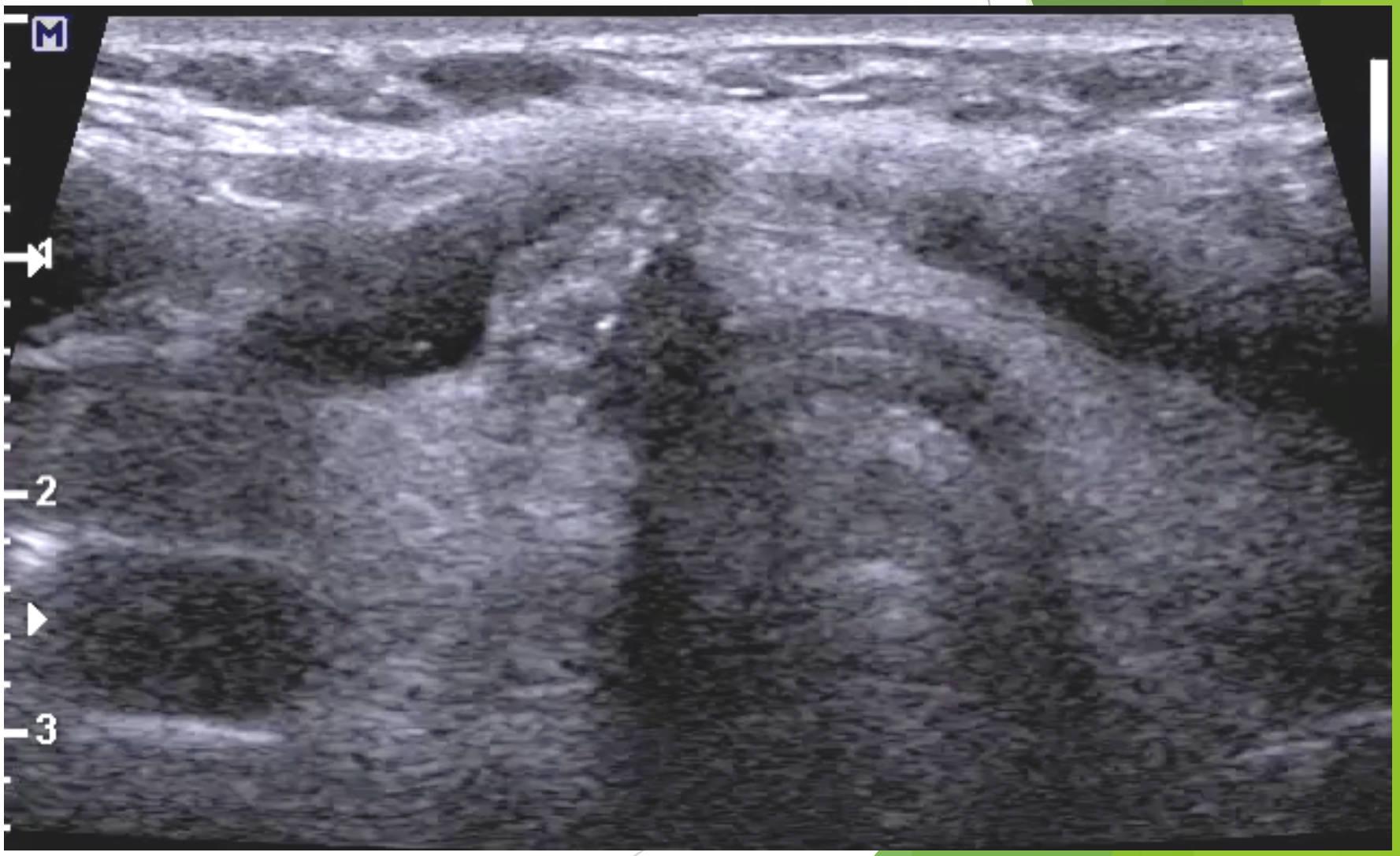

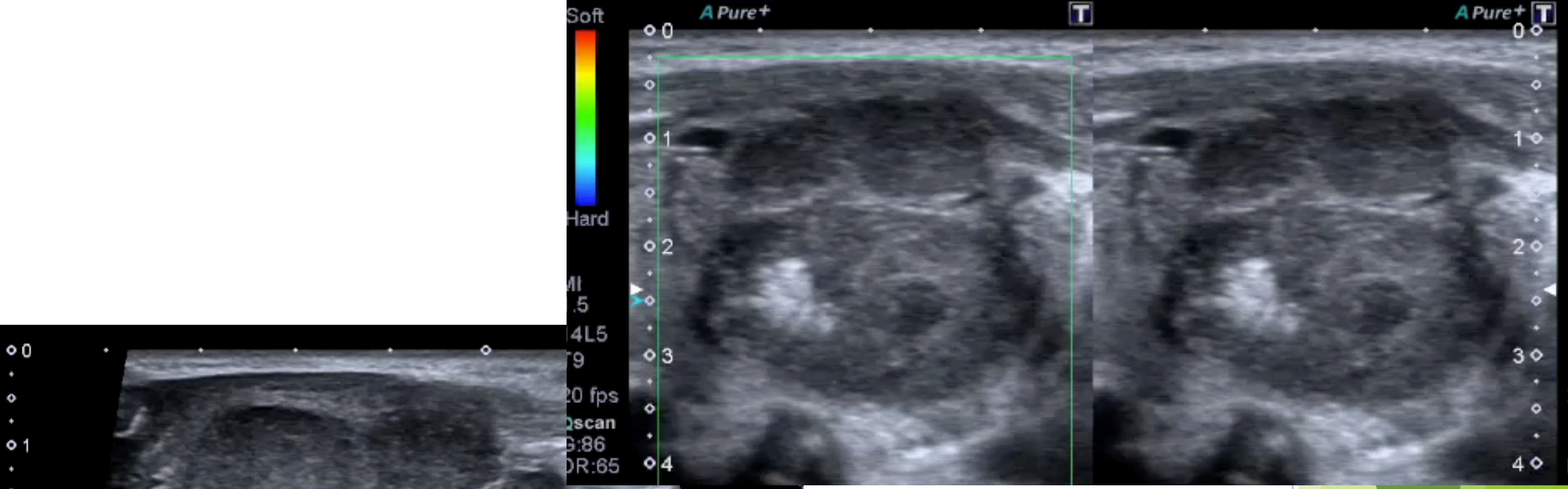

Histologie:
Anaplastisches (30 %)
gering differenziertes (50 %)
papilläres (15 %)
Karzinom

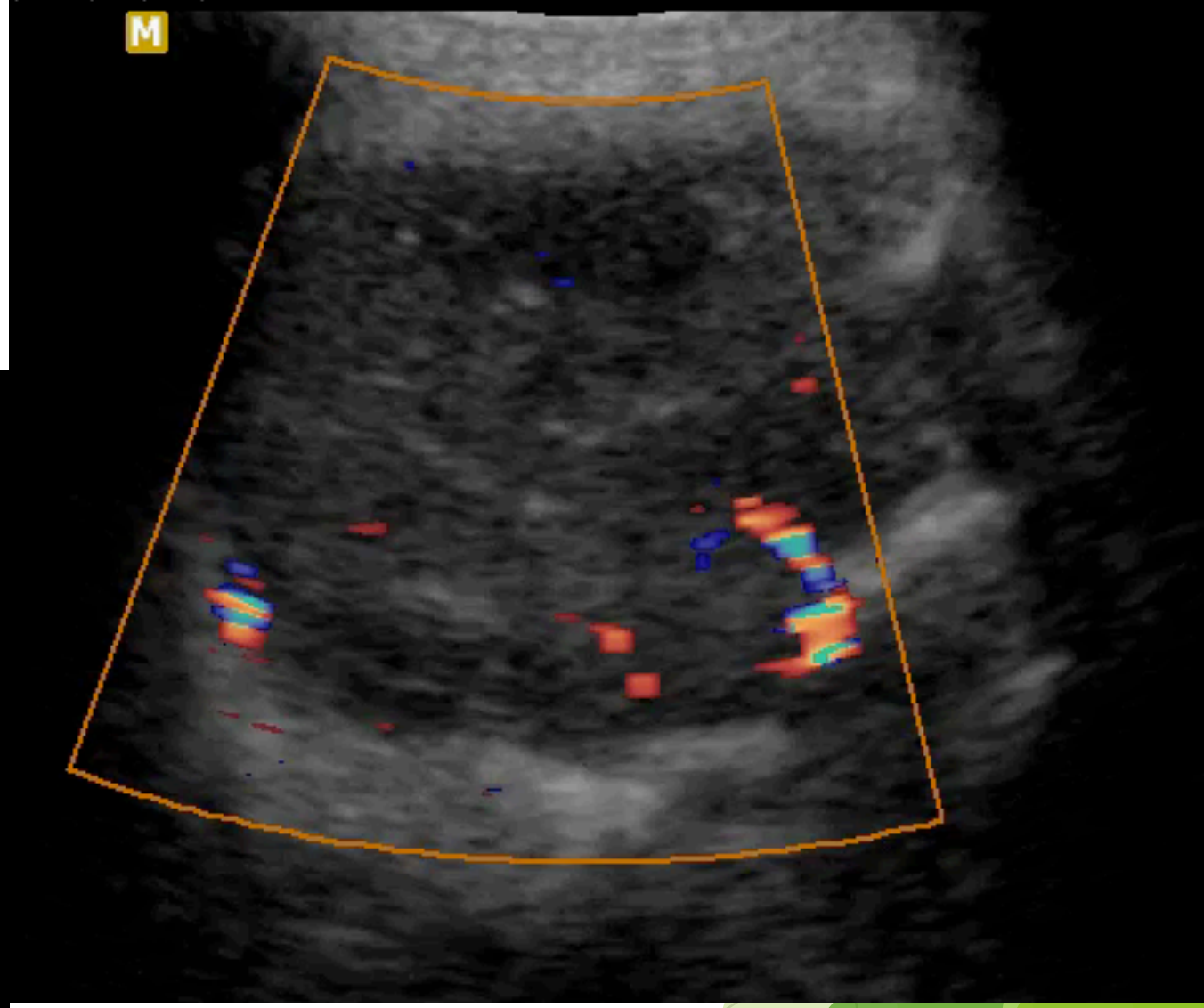

Follikuläres Schilddrüsen-Karzinom

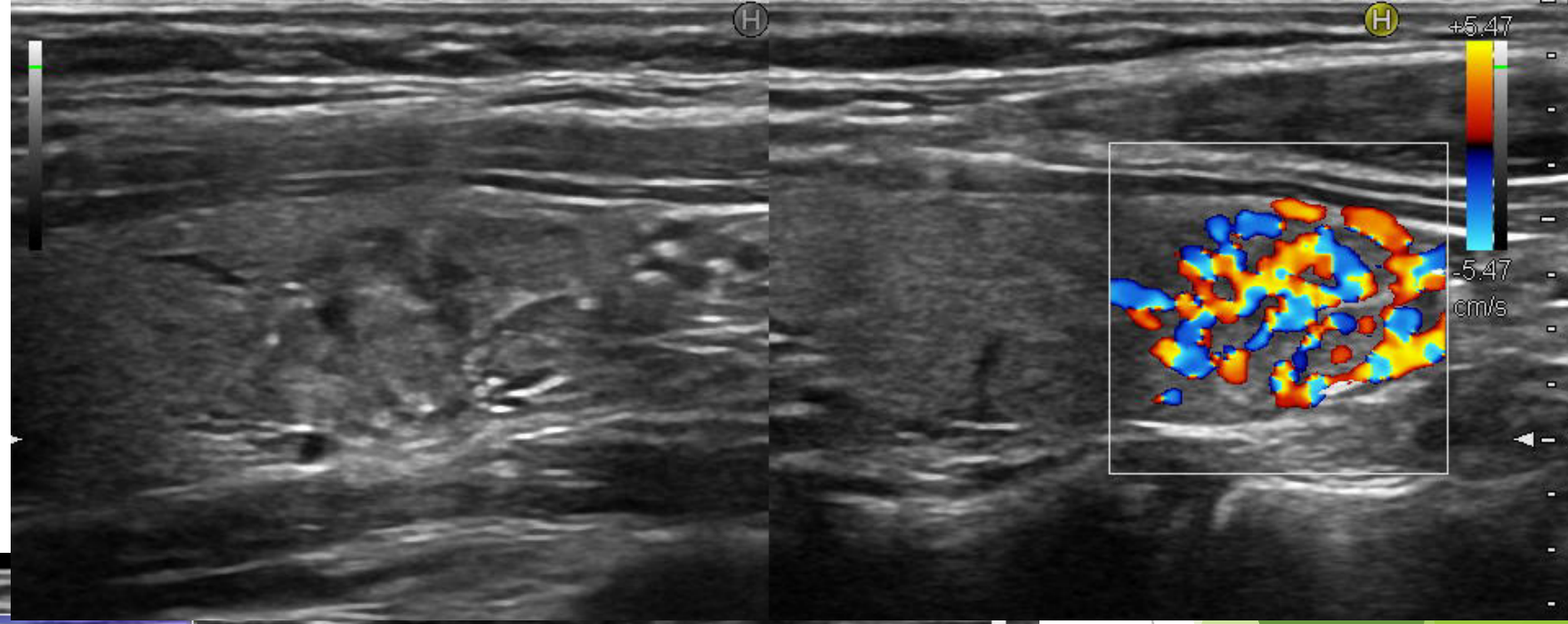

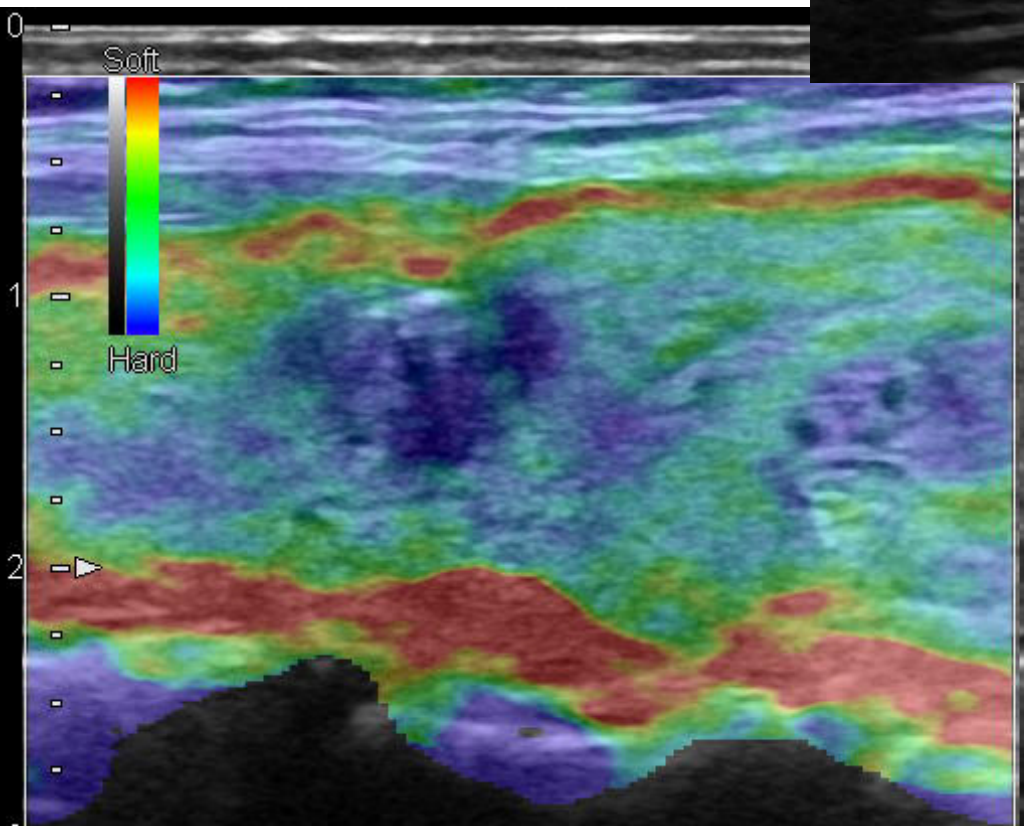

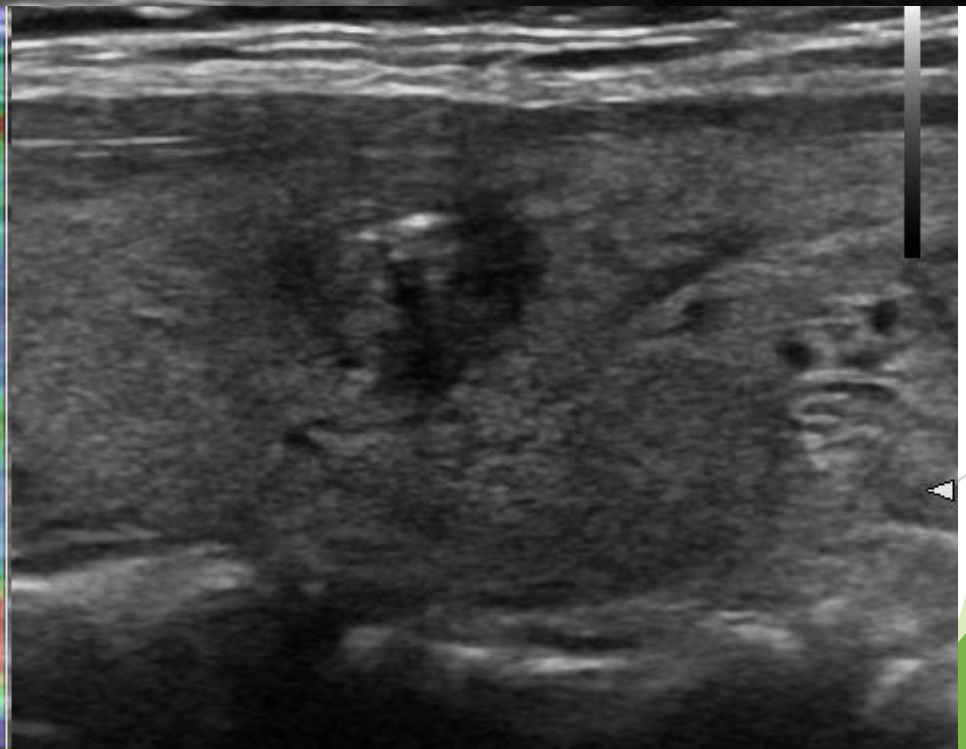

Papilläres Karzinom

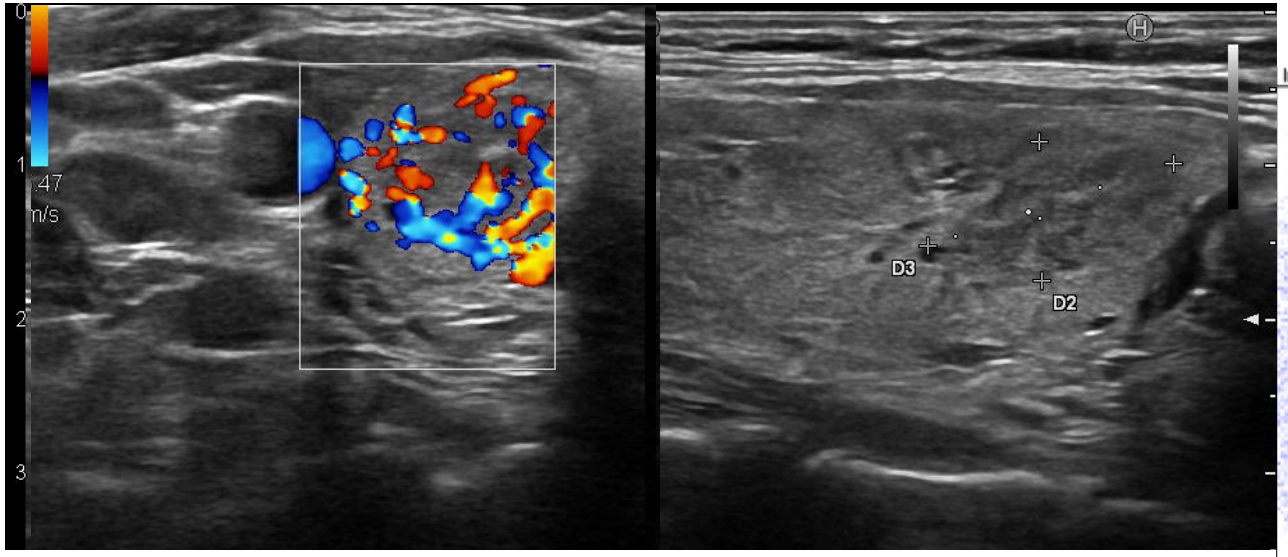

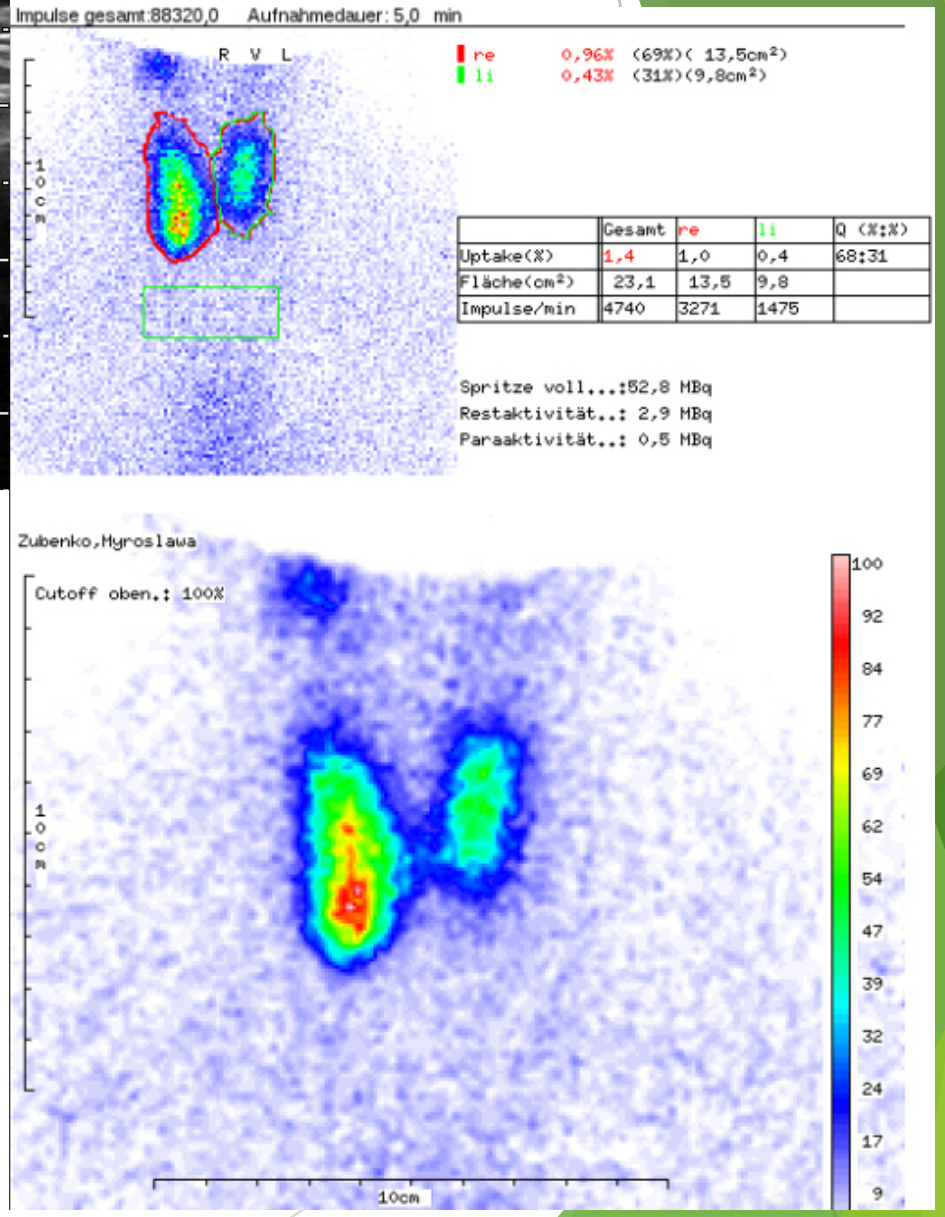

Autonomes Adenom

-sonogr. suspekt
-szintigr. eindeutig benigne

Thyreoiditis De Quervain

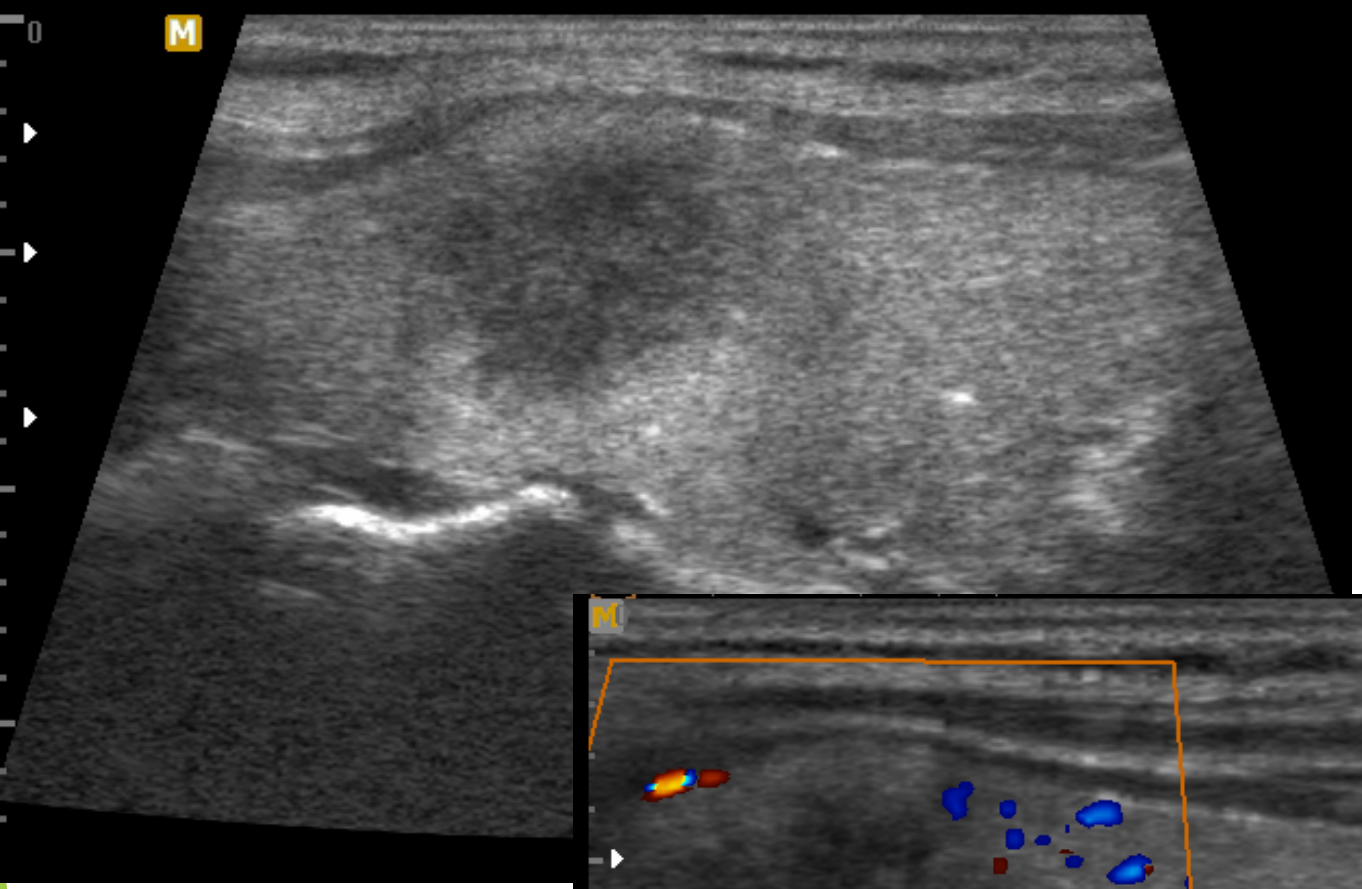

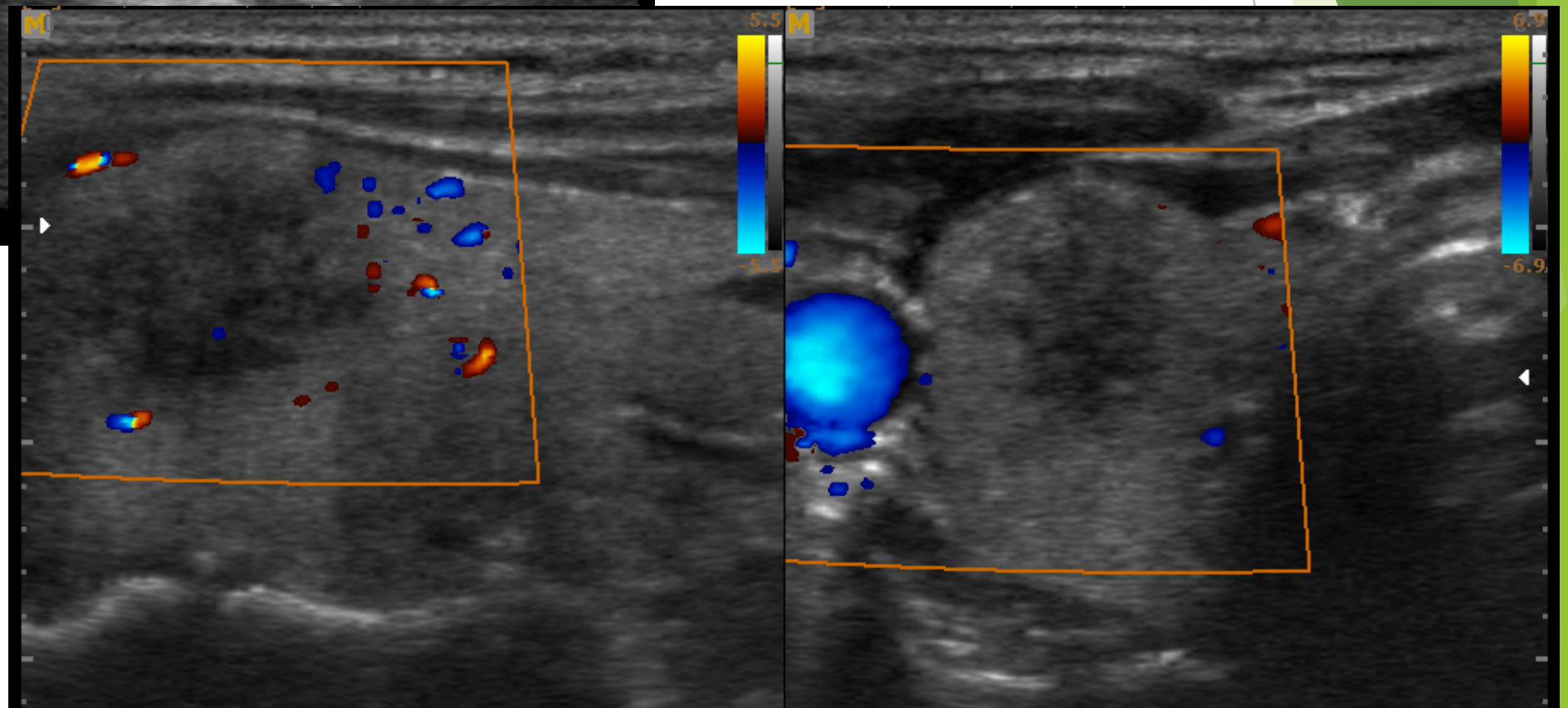

Thyreoiditis De Quervain

Fast immer schmerzhaft
Krankheitsgefühl,
Entzündungszeichen

Sonografisch
- unscharf und echoarm
- bizarr begrenzt
- nicht bis minimal perfundiert
(Abgrenzung zum Karzinom!)

Rückbildung unter
NSAR/Cortison

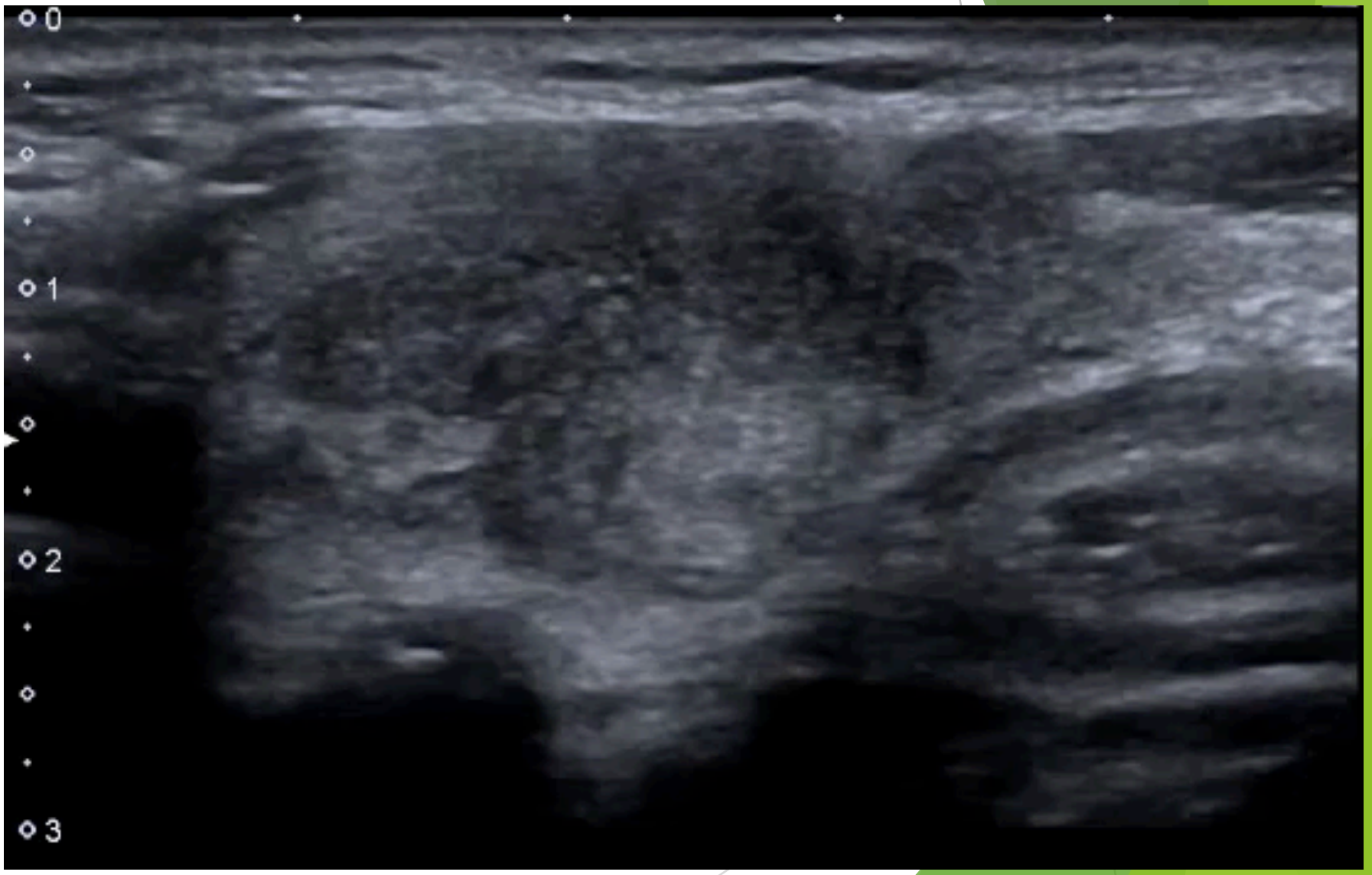

Thyreoiditis De Quervain

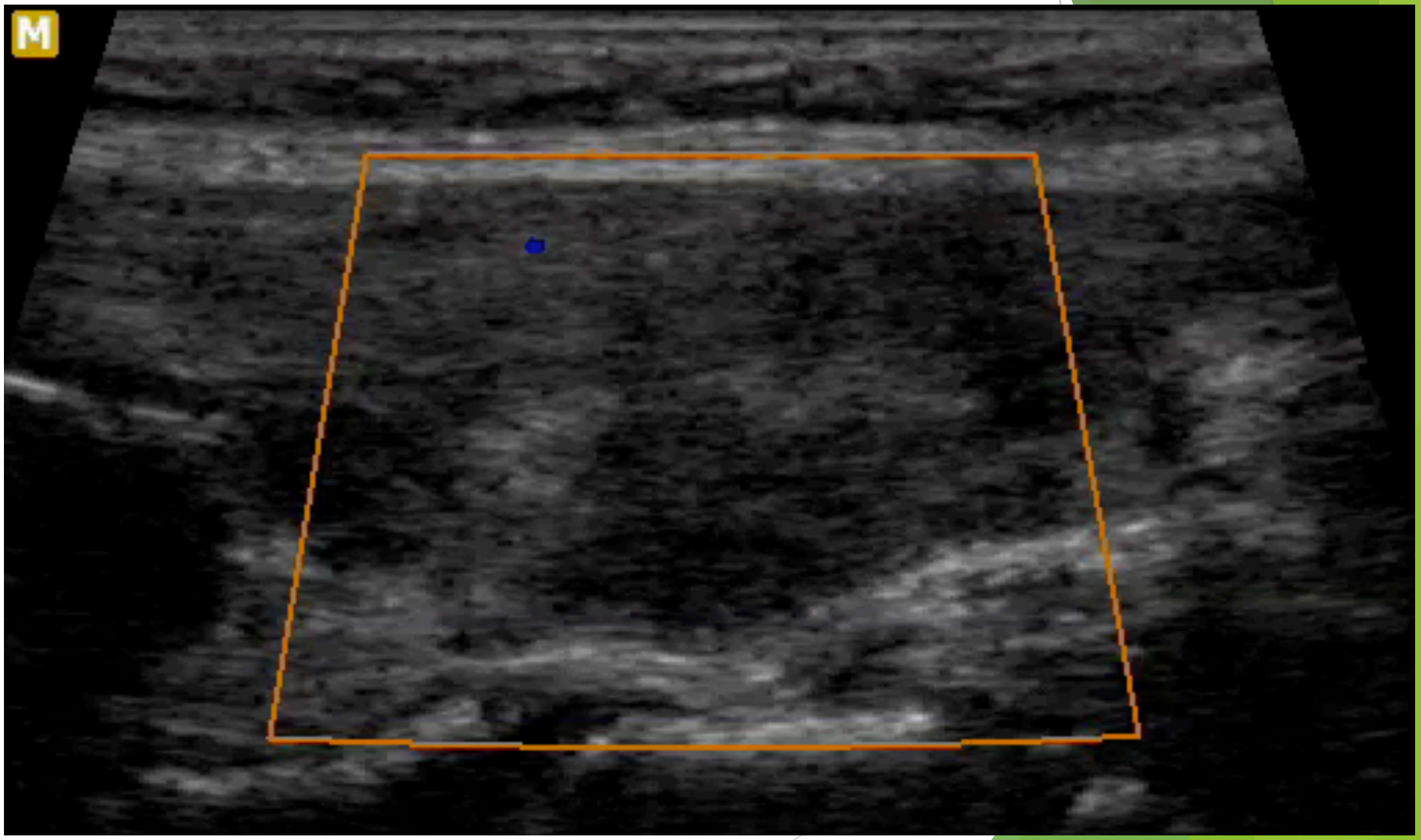

Schilddrüsenaplasie

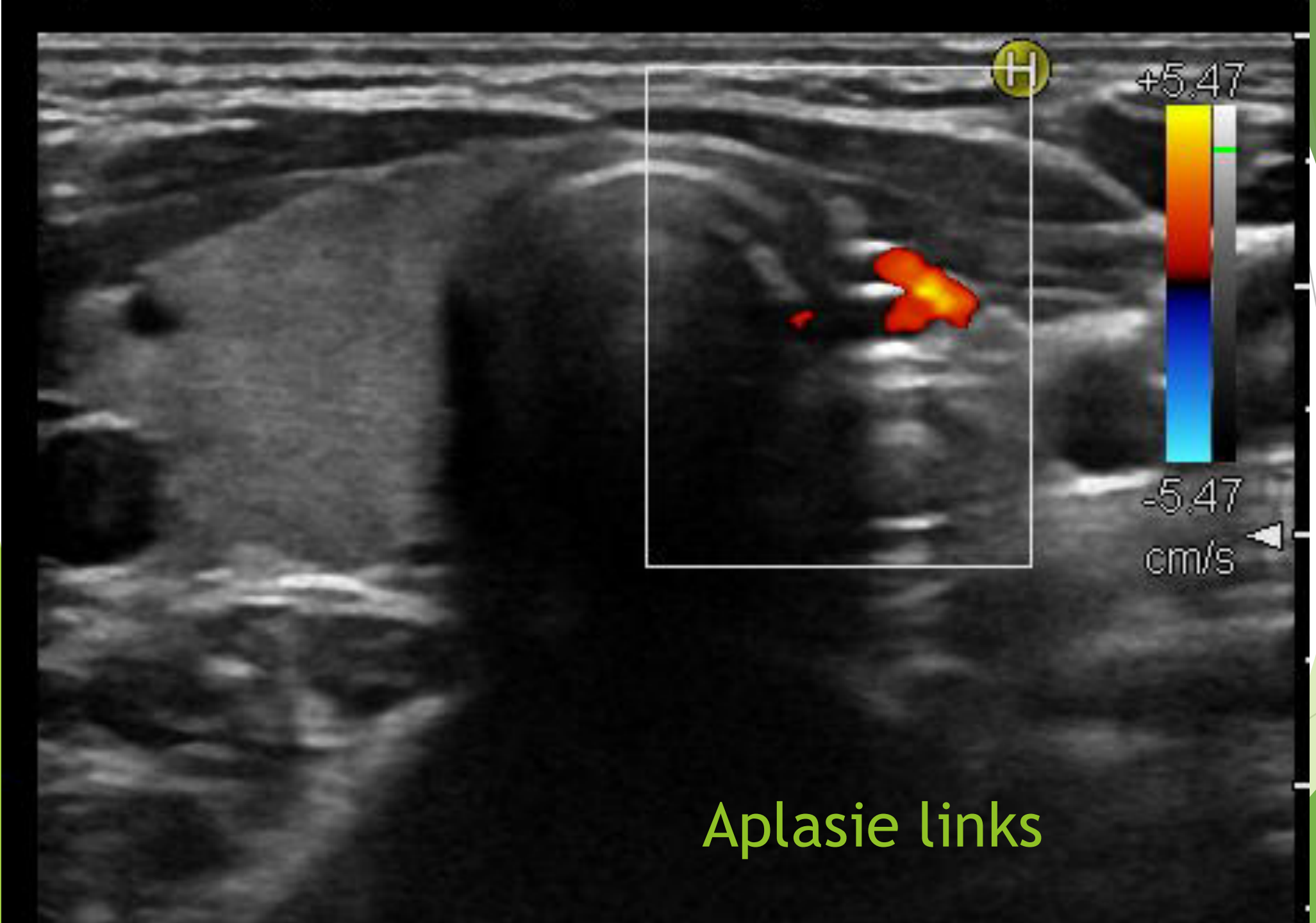

Aplasie links

M. Basedow

- Große, echoarme SD (sunglass Phänomen)

- Ggf. leicht inhomogen
- Farbe: Vaskuläres Inferno!

M. Basedow: sunglass-Phänomen

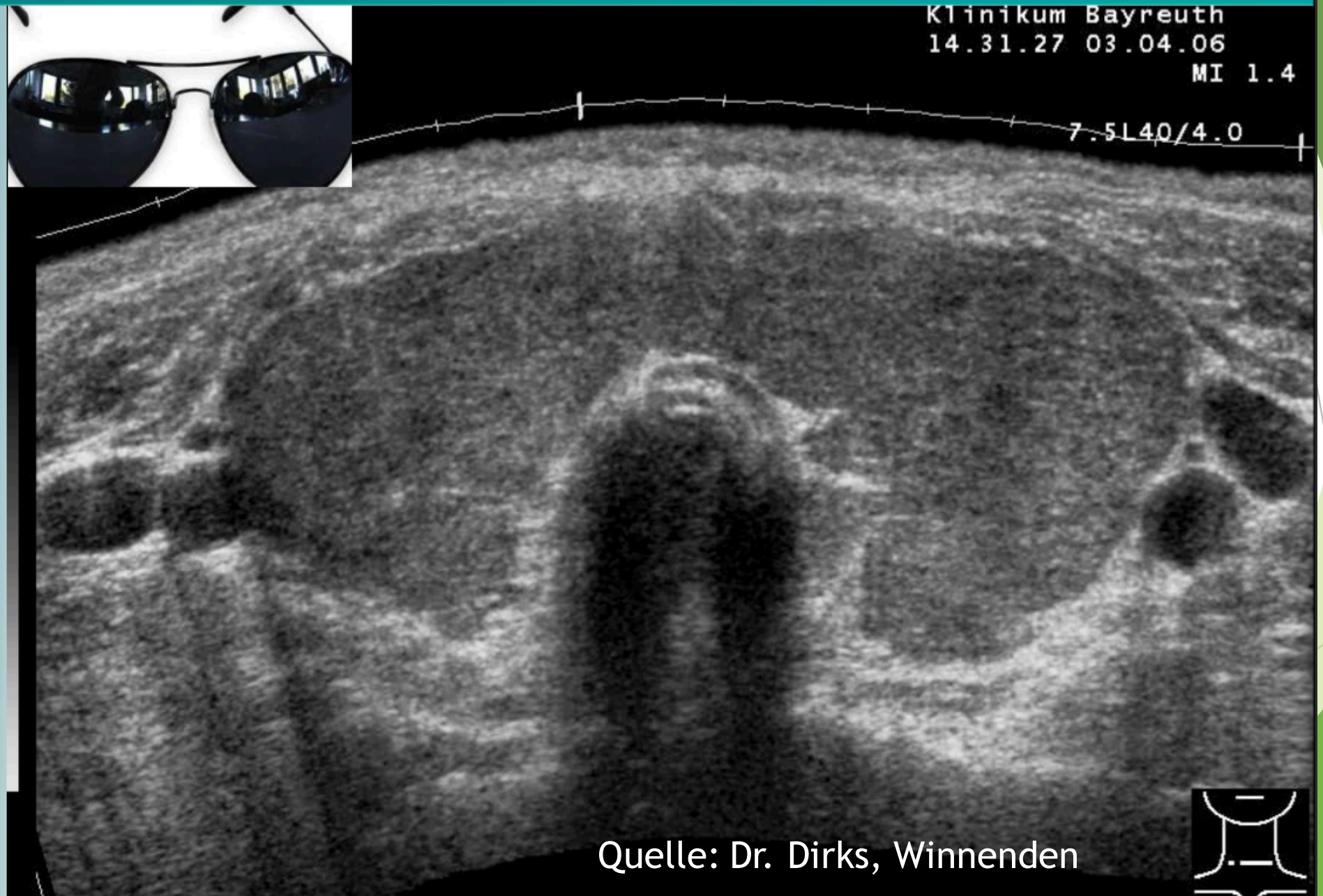

Quelle: Dr. Dirks, Winnenden

M. Basedow: Durchblutung !!

Quelle: Dr. Dirks, Winnenden

Morbus Basedow

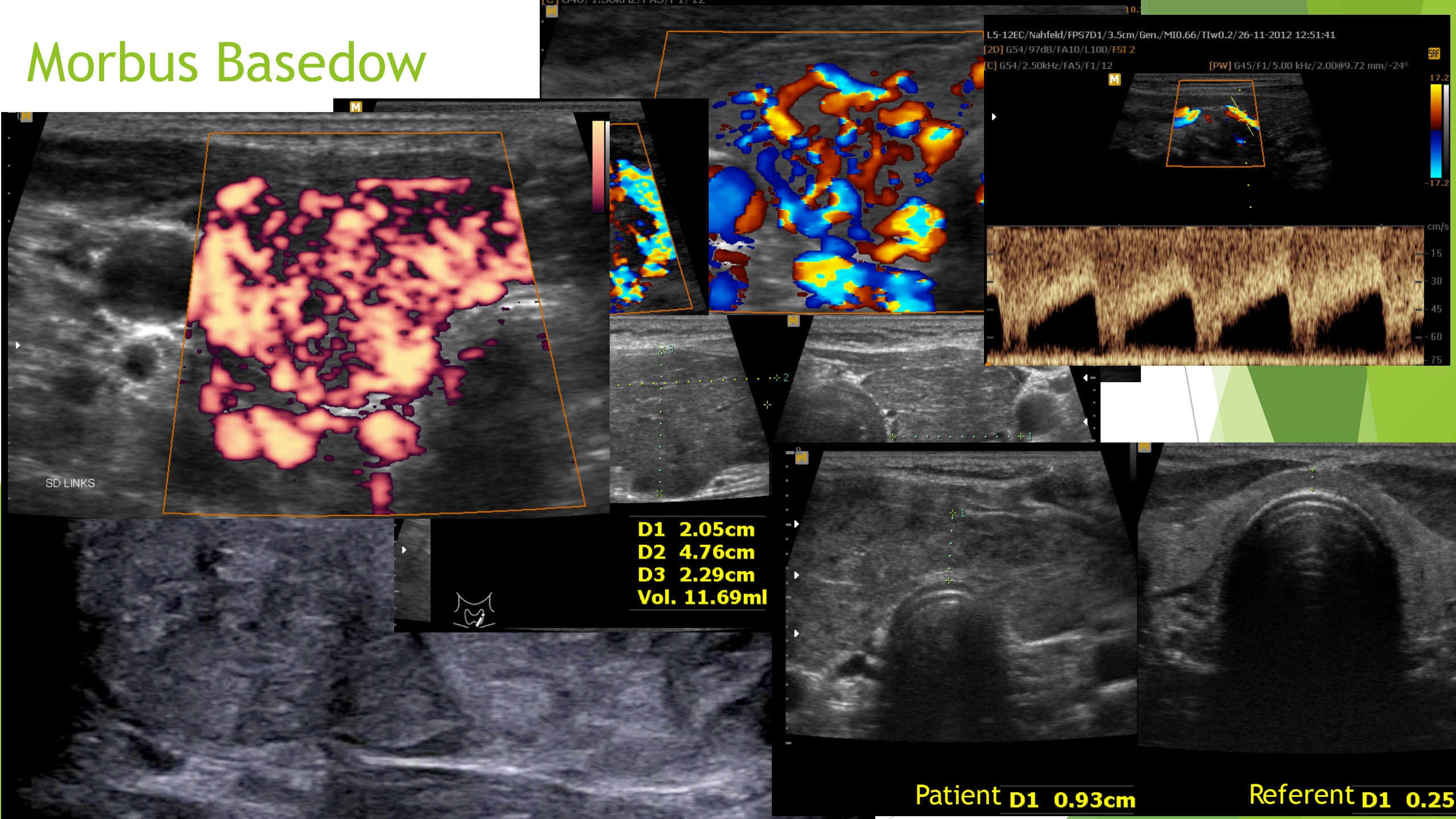

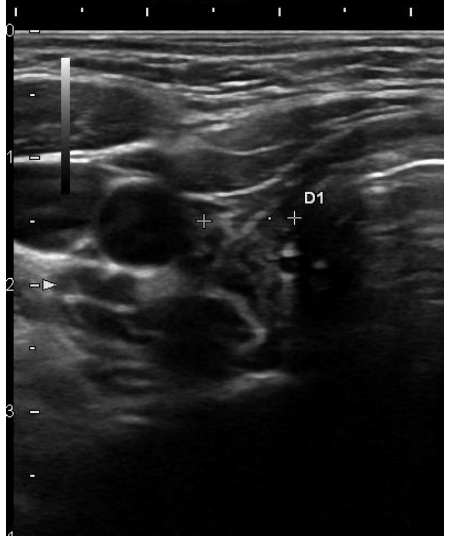

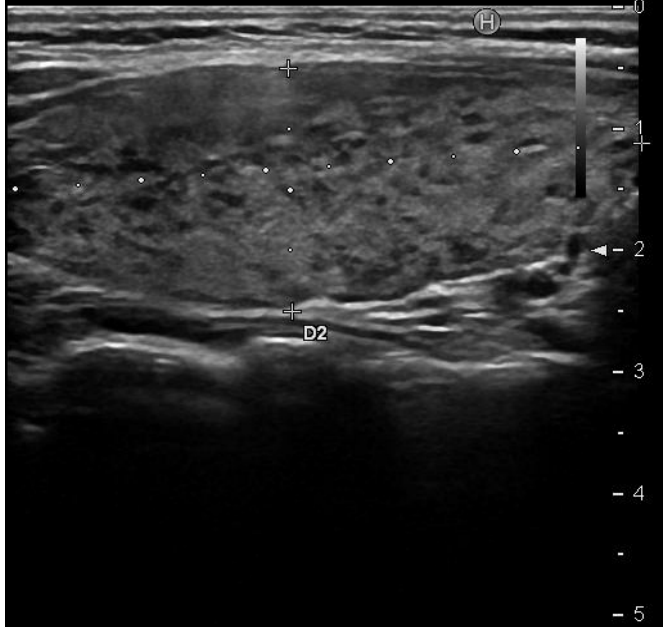

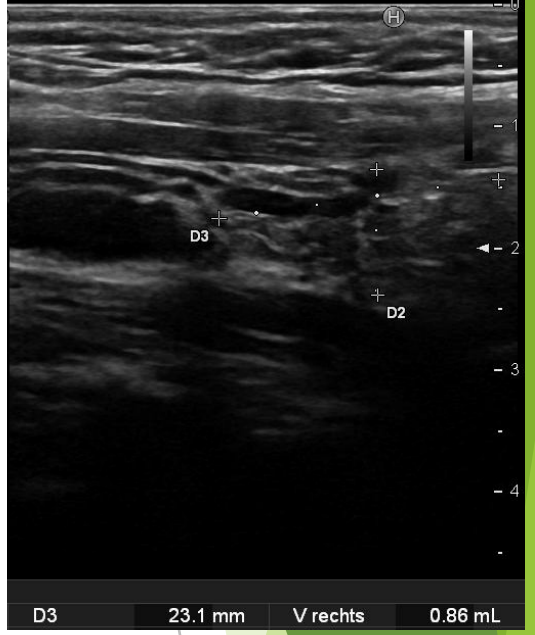

Hashimoto-Thyroiditis

meist kleines echoarmes kaum perfundiertes Organ
hypertrophe Form kann Basedow vortäuschen (TSH, TRAK, Szinti)

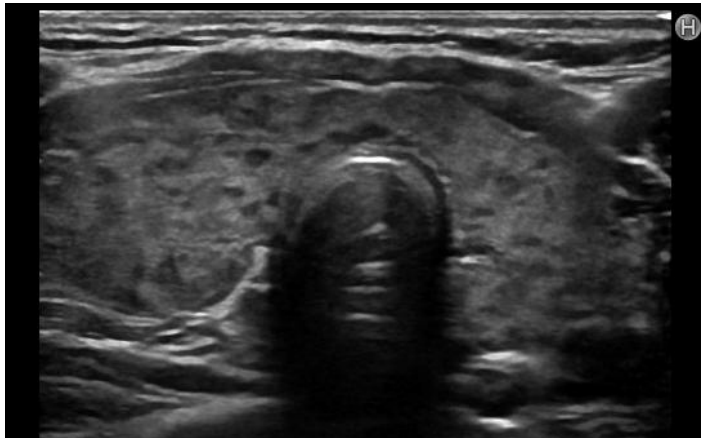

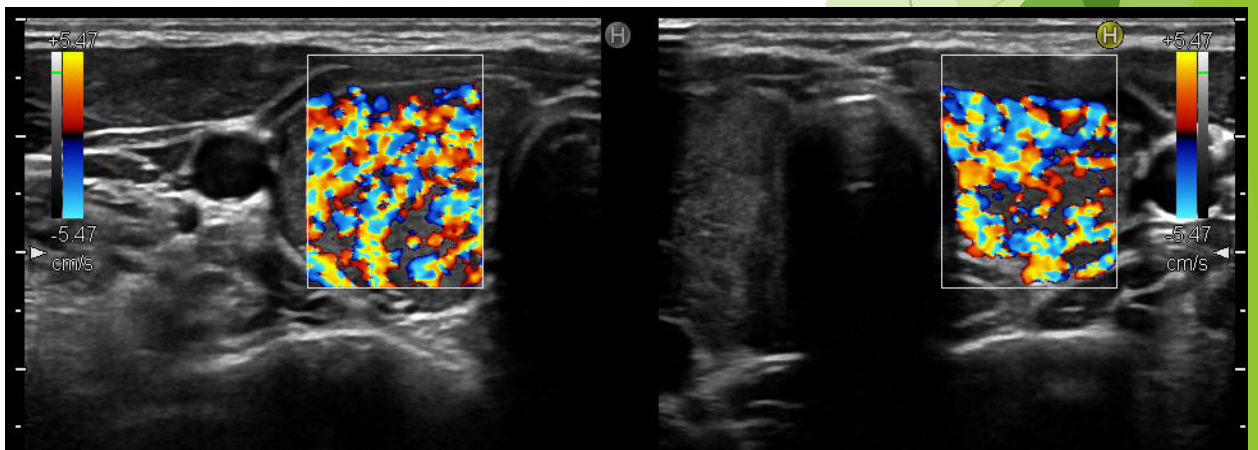

Roelfsema *et al., JCEM 2009, 94*

- Nicht jeder hohe TSH-Wert ist krankhaft

- Asymptomatische TSH-Werte bis 10 mU/l müssen nicht therapiert werden (ATA-Leitlinie)

- Ausgeprägter Leidensdruck mancher Hashimotopatientin hat meist keine thyreoidale Ursache und spricht daher **nicht** auf Dosisexperimente mit L-Thyroxin, T3-Präparaten o. ä. an

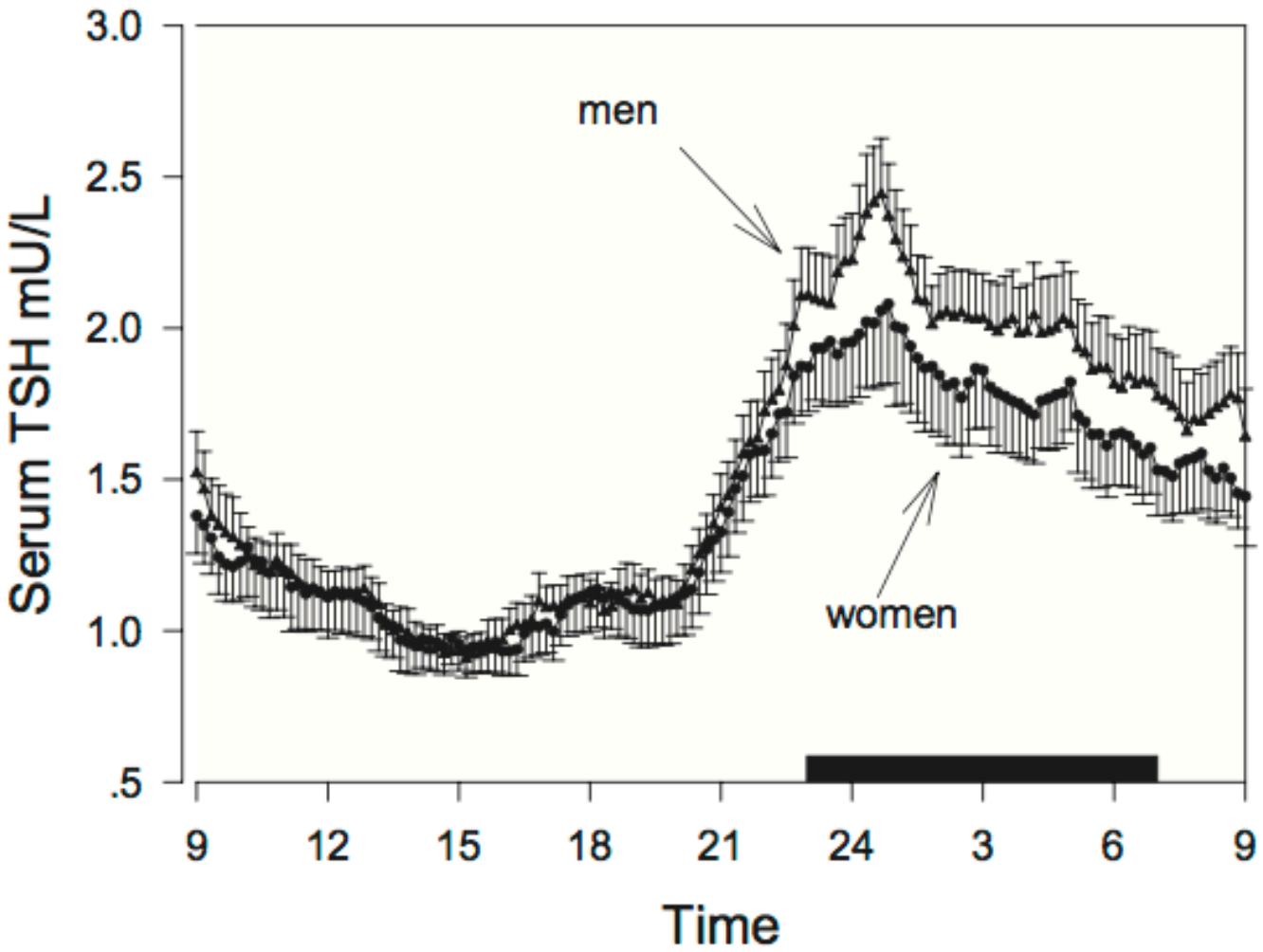

Hyperparathyroidismus

- Sekundär:
  - reaktiv bei Vitamin-D-Mangel
  - bei Niereninsuffizienz

- Primär:
  Hypertrophie einer Nebenschilddrüse
  Hypertrophie mehrerer Nebenschilddrüsen bei Multipler Endokriner Neoplasie Typ 1

  →MEN-1: neuroendokr. Tumore, Hypophysenadenom, prim. Hyperparathyroidismus

Nebenschilddrüse

Sensitivität und Spezifität der Sonographie

Autor	n	Sens.	Spez.
Rickes Ultraschall Med. 2003	89	86%	93%
Haber Clin Endocrinol 2002	120	77%	74%
Solorzano J Am Coll Surg. 2006	262	77%	80%
Sliperstein Surgery 2004	350	74%	78%

Σ Sensitivität 74-86%

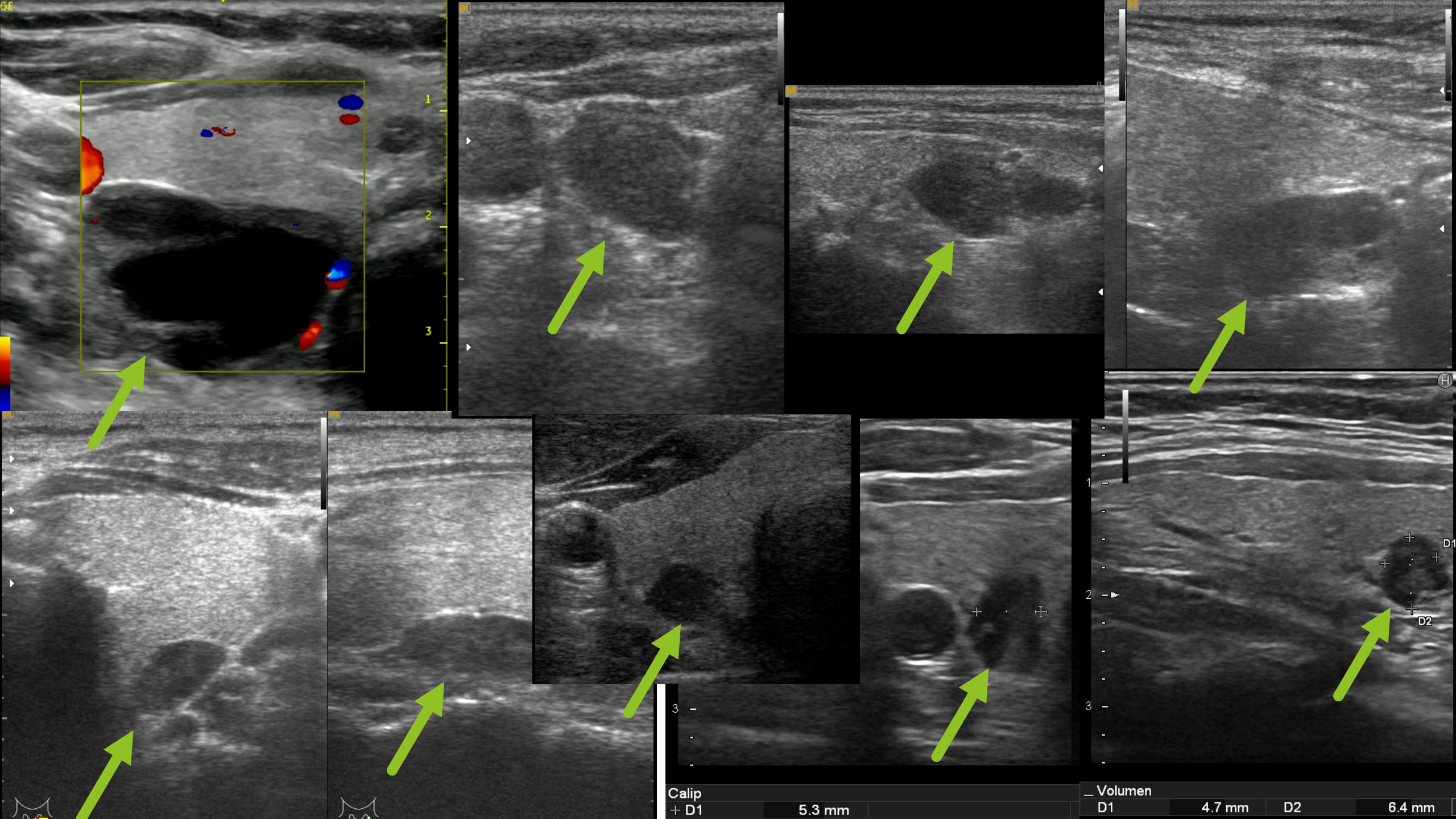
Calip
D1
5.3 mm
Volumen
D1
4.7 mm
D2
6.4 mm

Serienbeschreibung:Nebenschilddrüse
Radiopharmazeutikum 1:555,0 MBq (15,00 mCi) Sestamibi

Seriendatum:18.03.2016
Energiefenstergruppe 1:99m Technetium

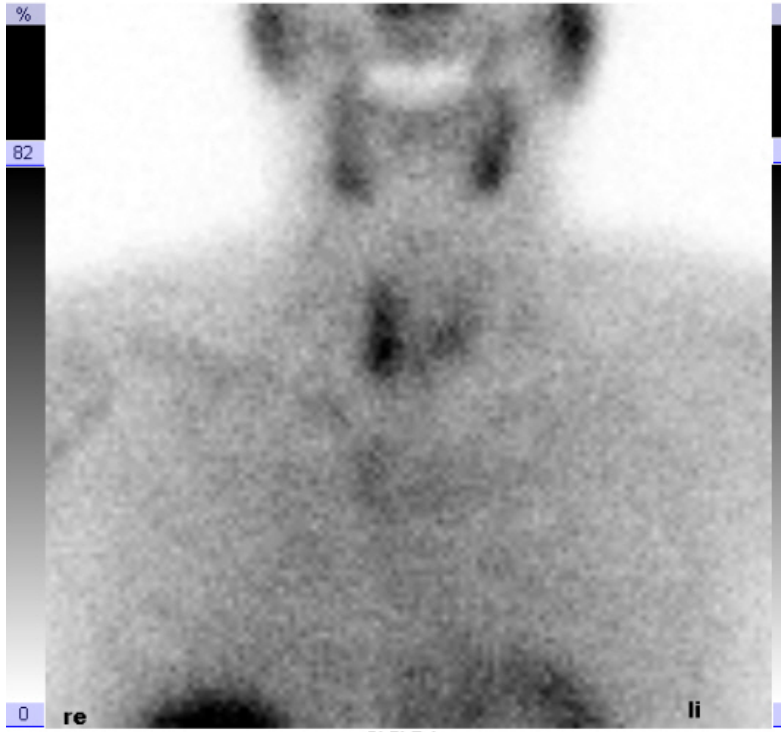

0'-5' P.I.

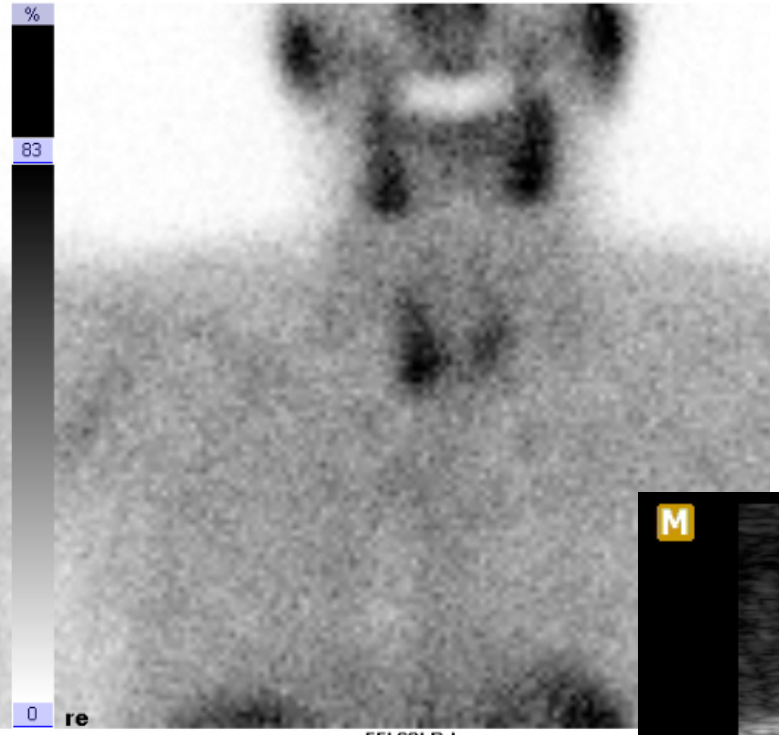

55'-60' P.I.

Gar nicht so selten:
Nebenschilddrüsen-Adenom im Thymus

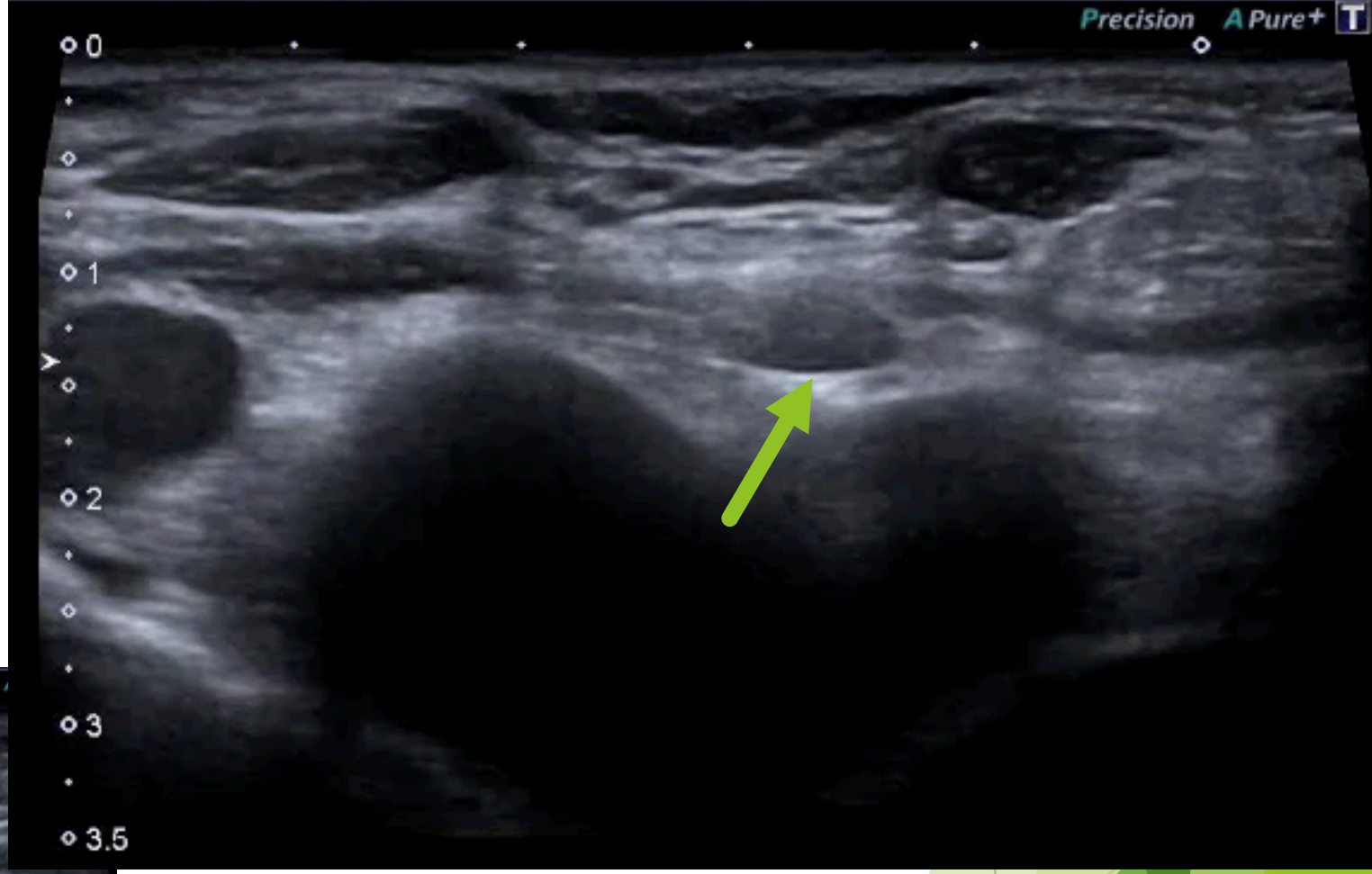

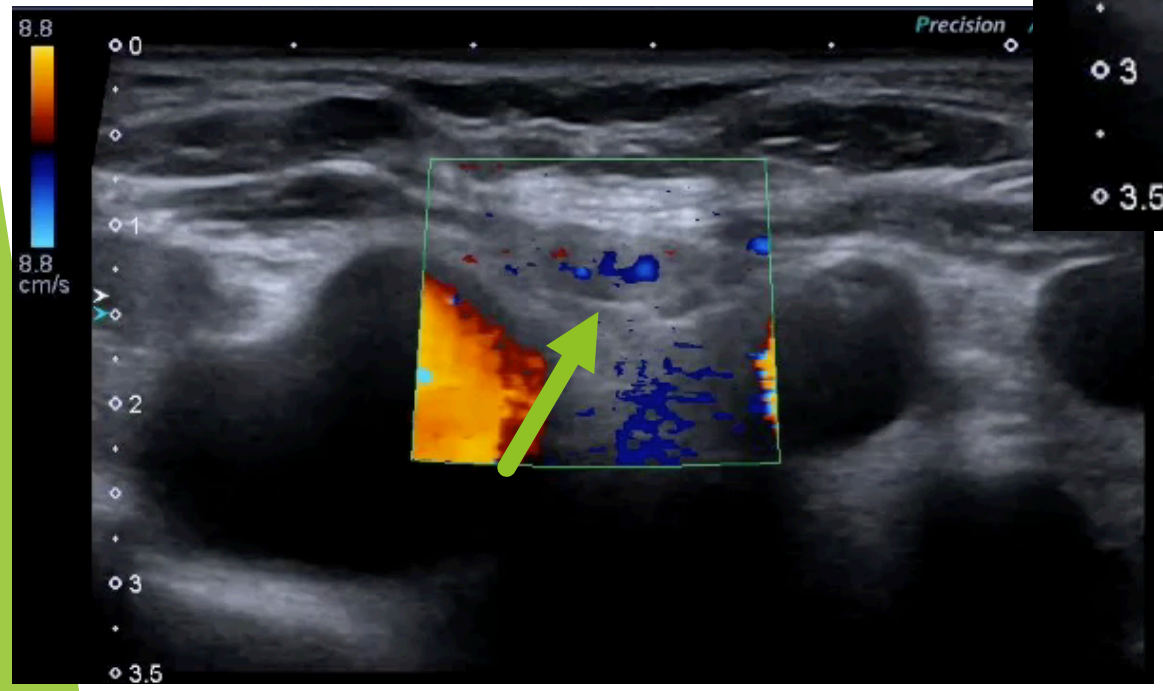

Ektope hypertrophe NSD im Thymus

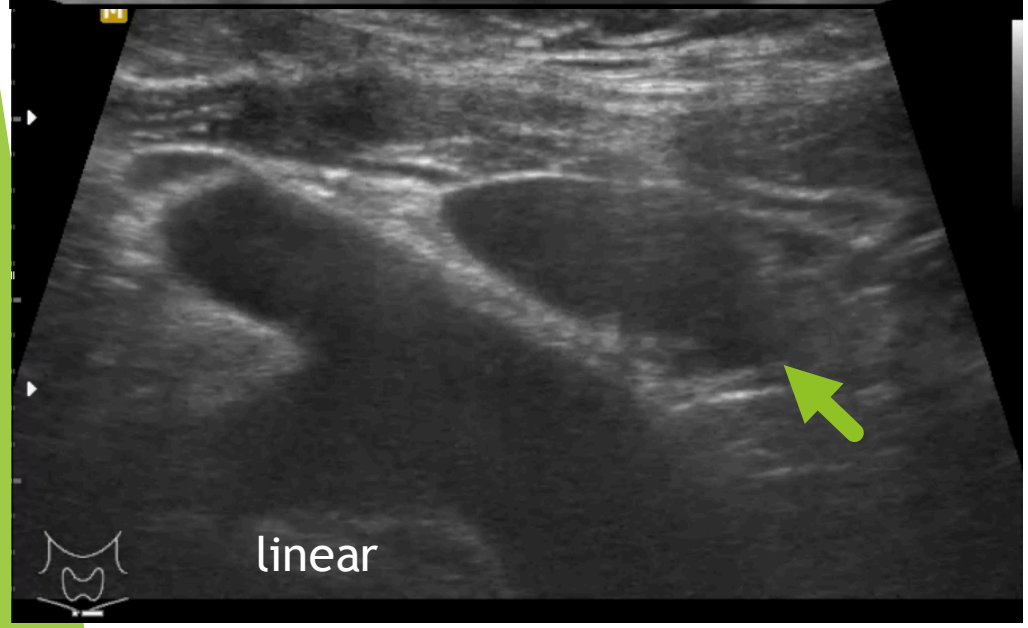

Suche
Von SD-Unterpol nach caudal retrosternal bis zum Aortenbogen schwenken
Thymus erstreckt sich vom SD-Unterrand ventral bis über den Aortenbogen

Trick (nicht nur hier)
Mit Konvexschallkopf starten, dann linear verwenden

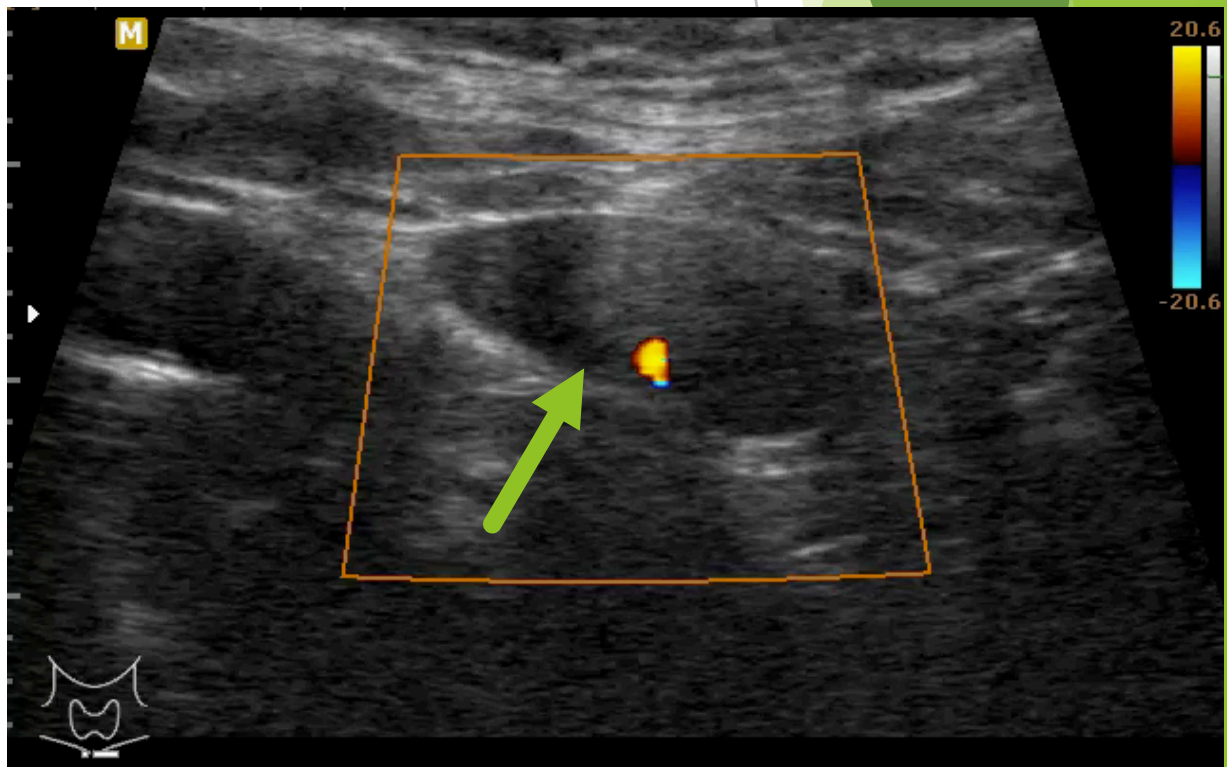

Thymus bei Jugendlichem

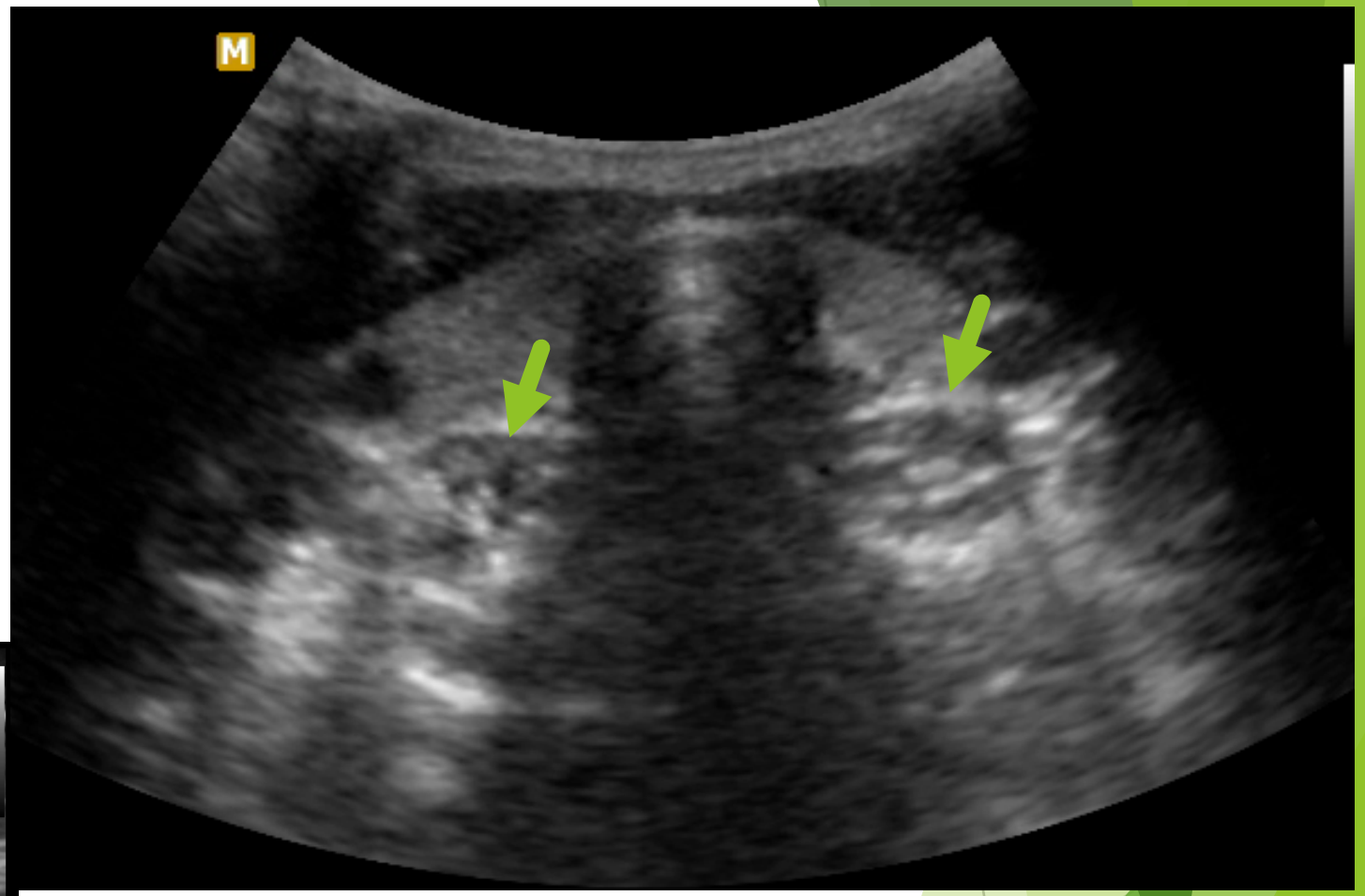

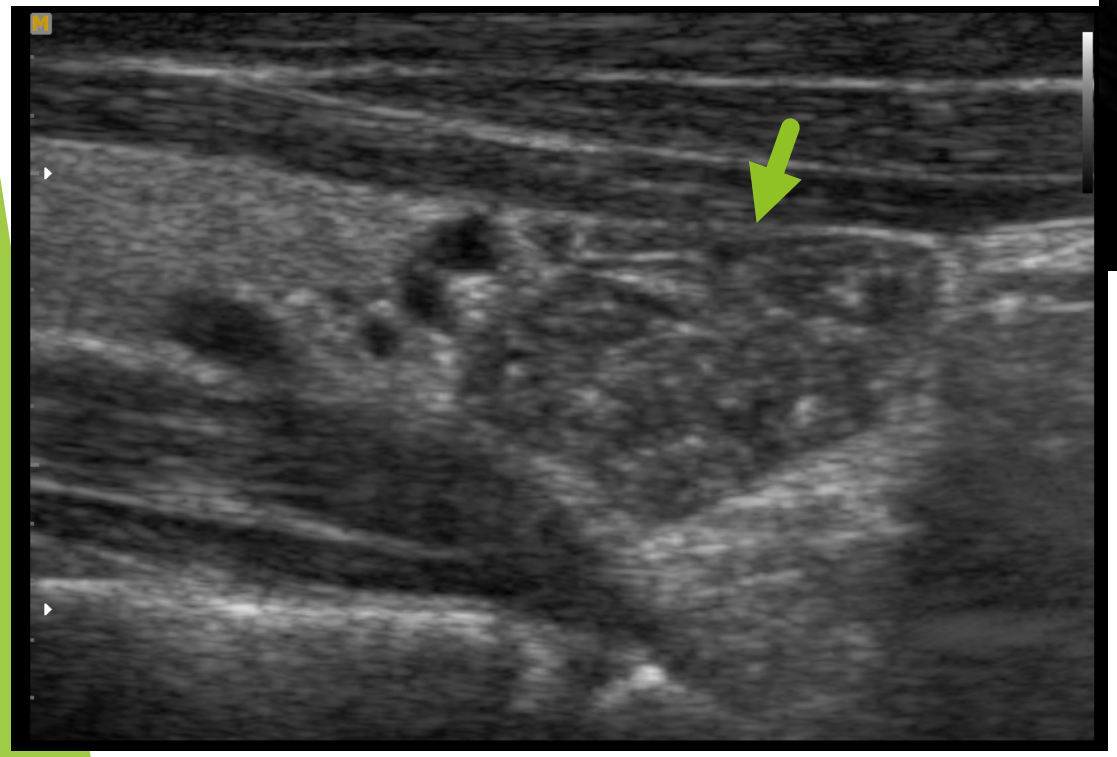

Herzlichen Dank

Mit Bildmaterial von

- Dr. Chrysanthi Anamaterou (Frankfurt)
- Dr. Klaus Dirks (Winnenden)

- Links, Fortbildungen und Kontakt:
  Dr. Matthias Lang
  www.ultraschallkolloquium.de

- Nutzung unter Quellenangabe erlaubt, bitte dann um kurze Mitteilung